Oncology Treatment Discovery

Editors-in-Chief

Vincent J. Cogliano

U.S. Environmental Protection Agency, USA

Chong Li

Chinese Academy of Sciences, China

BIO-BYWORD SCIENTIFIC PUBLISHING PTY LTD
(619 649 400)
Level 10
50 Clarence Street
SYDNEY NSW 2000
Copyright © 2023. Bio-Byword Scientific Publishing Pty Ltd.
Complimentary Copy

Oncology Treatment Discovery

Focus and Scope

Oncology Treatment Discovery is a peer-reviewed, open access journal. It accepts manuscripts relevant to experimental and clinical cancer research. The journal publishes the latest findings in cancer research, including preliminary results, repeated argumentation studies and negative results. The journal welcomes various types of submissions, e.g. research papers, clinical research reports, review articles. Content covers topics that advance clinical practice, challenge the status quo, advocate change in health policy, genomic instability, growth promoting signals, growth inhibitory signals, cell death, tumour microenvironment, carcinogenesis and cancer prevention and tackle issues related to global oncology.

About Publisher

Bio-Byword Scientific Publishing is a fast-growing, peer-reviewed and open access journal publisher, which is located in Sydney, Australia. As a dependable and credible corporation, it promotes and serves a broad range of subject areas for the benefit of humanity. By informing and educating a global community of scholars, practitioners, researchers and students, it endeavors to be the world's leading independent academic and professional publisher. To realize it, it keeps creative and innovative to meet the range of the authors' needs and publish the best of their work.

By cooperating with University of Sydney, University of New South Wales and other world-famous universities, Bio-Byword Scientific Publishing has established a huge publishing system based on hundreds of academic programs, and with a variety of journals in the subjects of medicine, construction, education and electronics.

Publication Headquarter

BIO-BYWORD SCIENTIFIC PUBLISHING PTY LTD
Level 10
50 Clarence Street
Sydney NSW 2000
Website: www.bbwpublisher.com
Email: info@bbwpublisher.com

2023, Volume 1 Issue 1

Table of Contents

1 **Keratocystic Odontogenic Tumor**
Alexandre AB de Lira, Belisse B da Cunha, Hiarles BS Brito, Gustavo Pina Godoy, Lelia MG Queiroz

7 **Adenomatoid Odontogenic Tumor in Mandible**
Roberto de A Azevedo, Braulio C Junior, Lucio CS Andrade, Carlos HS de Castro

13 **Biomarkers of Acute Appendicitis Severity: Diagnostic Test Study**
Ledmar J Vargas–Rodriguez, Jonathan F Barrera–Jerez, Kelly A Avila–Avila, David A Rodriguez–Mongui, Brayan R Munoz–Espinosa

23 **PET/CT in Staging and Treatment Evaluation of Non-Small Cell Lung Cancer**
Rosanna Elvira Morales Guzmán-Barrón, Edgar Amorín Kajatt, Richard Ledesma Vásquez, Sandro Casavilca Zambrano

32 **Prevalence of End-of-Life Signs and Symptoms in Glioblastoma Patients: A Descriptive and Retrospective Study**
Liliana Frazão Vasconcelos, Mafalda Monteiro Ferreira, José Maria Bandeira Costa

39 **Clinical Value Analysis of Pemetrexed Combined with Cisplatin in the Treatment of Non-Small Cell Lung Cancer**
Feifei Zhao

45 **Efficacy Analysis of Laparoscopic Myomectomy and Open Myomectomy in the Treatment of Uterine Fibroids**
Yaqin Yang, Liping Zhao

Call for papers – *Oncology Treatment Discovery*

Submission open for September - 2023

Dear Researchers,

Oncology Treatment Discovery is a peer-reviewed, open access journal. It accepts manuscripts relevant to experimental and clinical cancer research. The journal publishes the latest findings in cancer research, including preliminary results, repeated argumentation studies and negative results. The journal welcomes various types of submissions, e.g. research papers, clinical research reports, review articles. Content covers topics that advance clinical practice, challenge the status quo, advocate change in health policy, genomic instability, growth promoting signals, growth inhibitory signals, cell death, tumour microenvironment, carcinogenesis and cancer prevention and tackle issues related to global oncology.

The *Oncology Treatment Discovery* is published by Bio-Byword Scientific Publishing Company, it is a fast growing peer-reviewed and open access journal publisher, which is located in Sydney, Australia. As a dependable and credible corporation, it promotes and serves a broad range of subject areas such as medicine, construction, education and electronics for the benefit of humanity. By informing and educating a global community of scholars, practitioners, researchers and students, it endeavour's to be the world's leading independent academic and professional publisher.

All Bio-Byword journals are free from all access barriers, allowing for the widest possible global dissemination of their manuscripts and highest possible citations. Bio-Byword publisher online submission will go through a rapid peer review and production, making the process of publishing simpler and more efficient, which benefit from its user friendly online submission system that reduces the overall time from submission to publication.

Acceptance Notification: Within 21 days from the date of manuscript submission

Send your manuscript to the editor at: **info@bbwpublisher.com**

Kind regards,
Editorial Office
Oncology Treatment Discovery

Oncology Treatment Discovery, 2023, Volume 1, Issue 1
http://ojs.bbwpublisher.com/index.php/OTD

Keratocystic Odontogenic Tumor

Alexandre AB de Lira[1]*, Belisse B da Cunha[1], Hiarles BS Brito[1], Gustavo Pina Godoy[2], Lelia MG Queiroz[3]

[1]Paraíba State University (UEPB), Campina Grande 58429-500, Paraíba, Brazil

[2]Federal University of Pernambuco (UFPE), Recife 50670-901, Pernambuco, Brazil

[3]Federal University of Rio Grande do Norte (UFRN), Natal 59078-900, Rio Grande do Norte, Brazil

Corresponding author: Alexandre AB de Lira, alexandreabl_bg@hotmail.com

Copyright: © 2023 Author(s). This is an open-access article distributed under the terms of the Creative Commons Attribution License (CC BY 4.0), permitting distribution and reproduction in any medium, provided the original work is cited.

Abstract: The keratocystic odontogenic tumor (KOT) is a lesion that requires special considerations because of its clinical behavior and its specific histopathological aspects. The present study aims to show a case of KOT with its radiographic and histopathological features. In this study a 43-year-old female patient presented with a unilocular radiolucent image located in the posterior region of the mandibular body on the left side, extending to the ascending ramus, were observed on a panoramic radiograph. Further, she undergoes a CT scan followed by biopsy for histopathological examination. The pathological cavity was lined by parkeratinized epithelium with a basal layer arranged in a "palisade" pattern cells with nuclear hyperchromatism were observed, confirming that it was a KOT. Therefore, dental surgeons' knowledge of dental tumor of odontogenic tumor lesions, especially KOT is of fundamental importance to provide a correct diagnosis of these lesions, thereby preventing late diagnosis which can lead to the significant mutilation in the patients.

Keywords: Odontogenic tumor; Keratocystic odontogenic tumor; Enucleation

Online publication: April 19, 2023

1. Introduction

Firstly, it was described by Philipsen in 1956, since then it was called odontogenic keratocyst instead of odontogenic cyst. Due to its aggressive behavior and local recurrence, in 2005 World Health Organization (WHO) reclassified it as a keratocystic odontogenic tumor (KOT) [2]. It can be defined as a benign intraosseous tumor of odontogenic origin that exhibits a stratified parakeratinized paving epithelium lining [13]. This lesion can be associated with the basal cell carcinoma nevus syndrome, and an autosomal dominant disorder characterized by several developmental abnormalities, the presence of numerous KOTs, as well as the emergence of malignant skin neoplasms as the basal cell carcinoma types [14].

Osteochondritis dissecans (OCD) occurs in a wide age range, with a peak incidence rate is observed between the second and third decades of life, with a gradual decline in the incidence in the subsequent age groups [8]. The male gender is more affected by this type of lesion than the female, with a 2:1 ratio of male to female [3]. Radiographically, KOT presents itself as a uni- or multilocular radiolucent lesion, well circumscribed, can involve the non-erupted teeth, and also exhibiting displacement of impacted or erupted teeth, radicular resorption, and extrusion of the involved teeth [8].

The present work aims to discuss a case of OCD which is located on the left side of the mandibular crown, with rupture of the lingual, and superior cortical bone, by emphasizing on its radiographic and histopathological characteristics.

2. Case report

A female patient, Feoderma, 43 years old, resident in the City of Campina Grande (PB), was referred to the Dentistry Course of the Paraiba State University (UEPB) for evaluation of a radiolucent image observed by the prosthetist in a panoramic radiograph. The radiolucent image showing unilocular, located in the posterior region of the mandibular body on the left side, extending to the ascending ramus on the same side as shown in **Figure 1**.

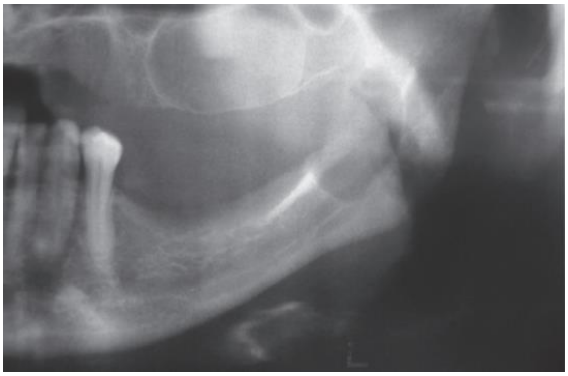

Figure 1. Unilocular radiocular image located on the left posterior region

During the anamnesis, the patient presented a good general health condition, with no history of drug allergies. During the extra- and intraoral physical exam, no volume increase or mucosal staining abnormalities was observed, however only painful symptoms were observed on the palpation.

From the above observation, a CT scan was requested to evaluate the mandibular area which harbored the lesion. Through axial, coronal axial, coronal, and longitudinal sections, a well-defined unilocular, hypodense image with cystic aspect located in the posterior region of the mandibular body on the left side, extending to the ascending ramus (**Figure 2**), which causes the rupture of the lingual cortical plates, and causing disruption of the lingual and superior cortices and mandibular canal deviation (**Figure 3**) was observed. Further, through clinical and radiographic exams, we reached the hypotheses diagnostic as KOT, multicystic ameloblastoma with a central giant cell lesion.

For subsequent diagnostic confirmation, the incisional biopsy was indicated for histopathological examination. It was observed that the histological sections which is stained in hematoxylin and eosin (HE) staining showed a pathological cavity lined stratified by parkeratinized epithelium with a corrugated epithelial surface, and basal layer arranged in a “palisade” pattern (**Figure 4**), which the presence of cells with nuclear hyperchromatism. The lesion stroma showed a little inflammatory infiltrate and was composed of loose fibrous connective tissue.

In view of these findings, the diagnosis of OCD, and the lesion was subsequently submitted to an excisional biopsy, with histopathological confirmation of the previously reported results.

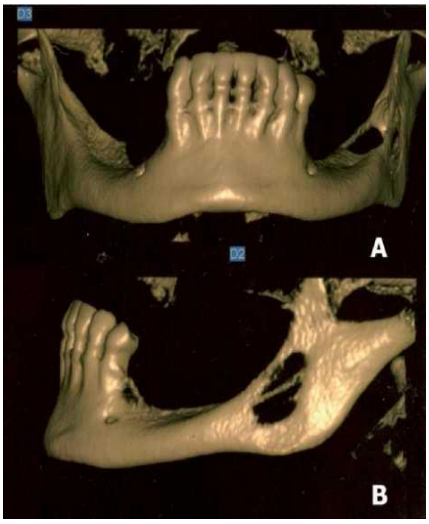

Figure 2. Three-dimensional recon section. Frontal (A) and lateral (B) views

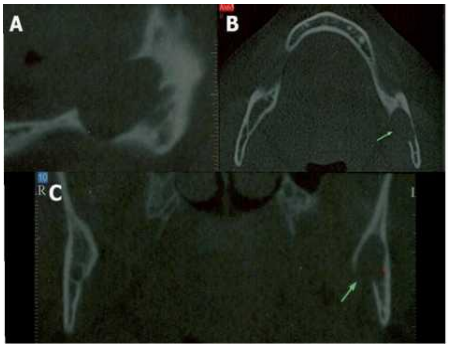

Figure 3. CT sects showing hypodense, unilocular image with cystic aspect, causing cortical rupture. longitudinal (A), axial (B) and coronal (C) slices

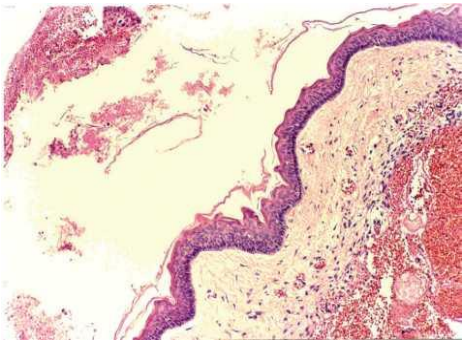

Figure 4. Parkeratinized stratified epithelium, showing a palisading basal layer, overlying a fibrous connective tissue stroma (HE, 100x)

3. Discussion

OCD is a lesion that requires special considerations due to its clinical behavior, and its specific histopathological aspects [5]. It can present case reports among patients from 7 to 93 years of age, with a higher incidence in the second and third decades of life, with a small prevalence in the male than female [1,5,7], and is most commonly found in the region of the mandibular third molar and ascending ramus [4,9,18]. In the present report, the study case contradicts with the literature with regard to the tendency of incident based on the age range and gender previously mentioned, where in this study it is a female patient in her

fifth decade of life. However, the region of higher incidence of the lesion is in agreement with the reviewed literature, where the case study presented the lesion as specified region.

According to Sousa et al., [19], the OCDs are initially asymptomatic, where mostly can be discovered during routine radiographic examination. The case reported here is similar to what was mentioned by the aforementioned authors, since the patient presented painful symptoms only on palpation, as well as the fact of having been referred to the specialized service due to verification of osteolytic lesions in panoramic radiography by the prosthodontist. The same authors also stated that, as they evolve, these lesions may cause painful symptoms, swelling or drainage.

Radiographically, the KOT described in the present study case as a unilocular radiolucent image with a cystic appearance, is in agreement report presented by Lopes et al., [12] and Dib et al., [5]. In general, the panoramic radiograph provides quality image showing the extent of the cystic lesion, and its relationship with adjacent structures. However, computed tomography shows more precise details about the expansion of the lesion, the location of involved teeth, and the topography of its margins (thickness and perforation of bone cortices) than conventional radiographs [6,15], which justifies the use of CT scan in the study case, making it is possible to verify the destruction of the lingual and alveolar bone cortical.

Given the clinical and radiographic findings of the study case, it was possible to reach diagnostic hypotheses as KOT, multicystic ameloblastoma with central giant cell tumor. However, as clinically no bulging of the buccal and lingual cortices was observed, the definitive diagnosis was KOT, since this lesion most often presents anteroposterior growth without expansion of the cortical bone, as stated by Dib et al., [5] and Gonzalez-Alva et al., [7]. Because the lesions are similar clinically and radiologically as seen previously, the importance of histopathological examination must be emphasized as a means of obtaining the definitive diagnosis. The case reported presented in this study is in agreement with the findings of Antunes et al., [1] who carried out an analysis of 69 cases of KOT, observed that the lesion histologically presented by KOT cases is a pathological cavity lined by parkeratinized stratified sidewalk epithelium, with a corrugated epithelial surface and a basal layer arranged as a “palisade,” with cells with nuclear hyperchromatism.

The lumen of the lesion revealed a clear or creamy liquid (thick and grayish) during microscopic examination consisted of keratin remnants, a fact that justifies the presence of a content of variable viscosity. When the needle punctures the lesion, it may show the viscosity content, where the greater the amount of keratin in the lumen of the lesion, the greater the viscosity of its content [11].

The KOT has a thin and friable capsule in most cases; therefore, it is difficult to be removed from the bone without fragmenting, requiring care during surgery [10,16]. It is noteworthy that the treatment and prognosis of OCDs do not reflect the critical point of disagreement among the authors surveyed. The two factors which are closely related are the severity and extent of the lesion, and the used therapeutic method.

According to Peterson et al., [17], the treatment of small tumors with a high degree of recurrence as the study case, is to perform enucleation of the lesion followed by curettage, and integration with LoPes Neto et al., [11] and Marques et al., [15] treatment method, who described a treatment based on total enucleation of the lesion followed by curettage of the surgical bed, the same technique was used in the study case.

The prognosis for KOT becomes favorable depending on the total removal of the lesion [16], emphasizing that, due to the friability of the loose conjunctive tissue stroma, the probability of remaining epithelial remnants in the region is high, which would invariably lead to a possibility of recurrence.

4. Conclusion

The knowledge of dental surgeons on tumor lesions of an odontogenic nature, especially of KOT, is of fundamental importance to provide a correct diagnosis, and timely treatment for such lesions, thereby preventing them from assuming large dimensions, subsequently leading to significant mutilation to the

patients.

Disclosure statement

The authors declare no conflict of interest.

References

[1] Antunes AA, Avelar RL, Santos TS, et al., 2007, Tumor odontogênico ceratocístico: análise de 69 casos [Keratocystic Odontogenic Tumor: Analysis of 69 Cases]. Rev Bras Cir Cabeqa Pescoqo, 36: 80–82.

[2] Barnes L, Everson JW, Reichart P, et al., 2005, Pathology and Genetics of Head and Neck Tumors. IARC Press, Lyon.

[3] Chirapathomsakul D, Sastravaha P, Jansisyanont P, 2006, A Review of Odontogenic Keratocyst and the Behavior of Recurrences. Oral Surg Oral Med Oral Pathol Oral Radiol Endod, 101(1): 95–99.

[4] Chye C, Singhh B, 2005, Rapid Cystic Development in Relation with an Impacted Lower Third Molar: A Case Report. Ann Acad Med Singapore, 34(1): 130–133.

[5] Dib JE, Ferreira MS, Guedes KP, et al., 2008, Tumor odontogenico ceratocistio em mandibula: relato de caso [Keratocystic Odontogenic Tumor in the Mandible: A Case Report. OCR], 10: 105–109.

[6] Fetter F, Grasselli S, Batista FC, et al., 2004, Ceratocisto odontogenico envolvendo CorPo e Angulo mandibular de paciente jovem: relato de Caso Clinico [Odontogenic Keratocyst Involving the Crown and Mandibular Angle of a Young Patient: A Case Report]. Stomatos Canoas, 10: 53–59.

[7] Gonzalez-Alva P, Tanaka A, Oku Y, et al., 2008, Keratocystic Odontogenic Tumor: A Retrospective Study of 183 Cases. J Oral Sci, 50(2): 205–212.

[8] Habibi A, Saghravanian N, Habibi M, et al., 2007, Keratocystic Odontogenic Tumor: A 10-Year Retrospective Study of 83 Cases in an Iranian Poulation. J Oral SCi, 49(3): 229–235.

[9] Kissi L, Benyahya L, Rifki A, 2006, Le Keratokyste isole: a propðs d'um Cas [The Power of Rocks: A Proposal for a Case]. Journal de Ordre des Dentistes du Quebec, 43: 321–328.

[10] Ladeinde AL, Ajayi OF, Ogunlewe MO, et al.,2005, Odontogenic Tumors: A Review of 319 Cases in a Nigerian Teaching Hospital. Oral Surg Oral Med Oral Pathol Oral Radiol Endod, 99(2): 191–195.

[11] Lopes Neto FC, Agostinho RM, Cruz FM, et al., 2000, Queratocisto odontogenico: relato de caso clinico [Odontogenic Keratocyst: Clinical Case Report]. HB Cientifica, 2000: 7.

[12] Lopes MWF, Souza GFM, Carvalho EJA, et al., Aspectos Clinico-morfol6gicos do queratocisto odontogenico: relato de Caso [Clinical and Morphological Aspects of Odontogenic Keratocyst: Case Report]. Odontologia Clin Cientif, 3: 61–66.

[13] Madras J, Lapointe H, 2008, Keratocystic Odontogenic Tumour: Reclassification of the Odontogenic Keratocyst from Cyst to Tumour. JCDA, 74(2):165–165h.

[14] Manfredi M, Vescovi P, Bonanini M, et al., 2004, Nevoid Basal Cell Carcinoma Syndrome: A Review of the Literature. Int J Oral Maxillofac Surg, 33(2): 117–124.

[15] Marques JAF, Neves JLN, Alencar DA, et al., 2006, Ceratocisto odontogenico: relato de caso [Odontogenic Keratocyst: Case Report]. Sitientibus, 34: 59–69.

[16] Neville BW, Damm DD, Allen CM, et al., 2004, Patologia: oral e maxilofacial [Pathology: Oral and Maxillofacial], Guanabara Koogan, Rio de Janeiro.

[17] Peterson LJ, Ellis E, Hupp JR, et al., 2005, Cirurgia oral maxilofacial contemporanea [Pathology: Oral and Maxillofacial], Elsevier, Rio de Janeiro, 521–524.

[18] Ramos RQ, Vieira EH, Gabrielli MFR, et al., 2001, Queratocisto odontogenico: revisao da literatura [Odontogenic Keratocyst: A Review of the Literature]. Rev Paul Odontol, 2001: 37–40.

[19] Sousa FACG, Vieira EMM, Kantorski KZ, et al., 2007, Queratocisto odontogenico: um estudo retrospective [Odontogenic Keratocyst: A Retrospective Study]. Rev Pos-Grad, 13: 324–327.

Publisher's note

Bio-Byword Scientific Publishing remains neutral with regard to jurisdictional claims in published maps and institutional affiliations.

Oncology Treatment Discovery, 2023, Volume 1, Issue 1
http://ojs.bbwpublisher.com/index.php/OTD

Adenomatoid Odontogenic Tumor in Mandible

Roberto de A Azevedo[1], Braulio C Junior[2], Lucio CS Andrade[1], Carlos HS de Castro[2]*

[1]Hospital Santo Antônio, Santo Antônio de Jesus 44571-013, Bahia, Brazil

[2]Federal University of Bahia, Ondina 40170-110, Salvador, Brazil

***Corresponding author:** Carlos H. S. de Castro, carloshsilveirac@hotmail.com

Copyright: © 2023 Author(s). This is an open-access article distributed under the terms of the Creative Commons Attribution License (CC BY 4.0), permitting distribution and reproduction in any medium, provided the original work is cited.

Abstract: The adenomatoid odontogenic tumor is a relatively infrequent lesion that mainly affects females in the second decade of life, and its predicted site is the anterior region of the mandible with the lesion usually associated with the crown of the tooth. In this study, a case of adenomatoid odontogenic tumor in the anterior region of the mandible is reported together with its clinical, radiological, and histological findings and surgical treatment.

Keywords: Adenomatoid odontogenic tumor; Adenoameloblastoma; Odontogenic tumor

Online publication: April 19, 2023

1. Introduction

Adenomatoid odontogenic tumor (AOT) is a relatively uncommon lesion of odontogenic epithelium origin, which was first described by Gash in 1934, however, it was Stafne (1948), who is the first to recognize it as an entity. Until then, the lesion was considered as a variant of ameloblastoma, and was called as odonAOTmeloblastoma [1]. Only in 1969, Philipsen and Birn established its current denomination, followed by recognition by the World Health Organization (WHO), and in 1971 it was recognized as a benign neoplasm of ectodermal origin [2,3].

Clinically, its presented as a slow-growing lesion, with little or no painful symptoms, and causing bone expansion. It affects the region of canines and premolars, both in the maxilla and mandible with a ratio of 2:1 respectively [4-6].

In addition, it is considered as an infrequent lesion that represents approximately 3% of total the total odontogenic tumors cases. Philipsen (1991) conducted a study with 499 cases of AOT, in which he found that the female gender is more affected compared to male gender with a proportion of 2:1 respectively, and it is diagnosed at a restricted age range between 10 to 30 years with most cases appearing at the second decade of life [7-10]. The intra-osseous is more common in the maxilla than in the mandible with a ratio of 2.1:1 respectively, and the peripheral is found almost exclusively in the anterior region of the maxilla [11,12].

Radiographically, AOT presents itself as a radiolucent area with well-defined contours by a cortical bone, and depending on the stage of maturation of the lesion, it may or may not contain radiopaque foci compatible with calcified zones [13-15]. In contrast, the lesion may or may not be associated with an unerupted tooth, of which 60% are canines [16,17].

In addition, Philipsen subclassified the AOT according to two variants [8] as described below:

(1) Follicular: Where the tumor is associated with the crown of an unerupted tooth, and corresponds to

73 % of the intra-bone lesions. This variant is often confused with dentigerous cyst.

(2) Extra-follicular: Where the tumor is not associated with an unerupted tooth, but is found in an interradicular position, and in the most cases causing root separation of the units which are neighboring the lesion. In these cases, the differential diagnosis is made with residual cyst and lateral periodontal cyst.

Histologically, the proliferation of epithelial cells is similar to the preameloblasts that is group in masses, forming a duct-like structures called pseudoducts. In these masses, the cells are in a cuboidal shape [18,19]. In some areas, these pseudoducts are filled with eosinophilic material, and in other regions this material is found between these pseudo-ducts [10,20-22].

The diagnosis of AOT should be well differentiated from other lesions, such as ameloblastoma. Since the prognosis of AOT is much more doubtful, due to its aggressiveness and its association with unerupted teeth, therefore the dentigerous cyst should be included [9,23,24]. With the presence of residual cyst, lateral periodontal cyst, and based on the presence of radiopaque foci, a differential diagnosis should be made by calcifying the lesions into an odontogenic cyst or epithelial odontogenic tumor [4]. Considering that AOT is a benign and nonaggressive tumor, characterized by a slow and progressive growth, low tendency to recurrence, and by the presence of a capsule indicating the absence of invasion of the surrounding tissues, the treatment choice is conservative surgery by excision and curettage [17,19,25]. Further, depending on the position and involvement of the unerupted tooth associated with the lesion, a decision will be made either the tooth should be preserved or not with orthodontic traction [6].

This article reports a case of Adenomatoid Odontogenic Tumor located in the mandibular symphysis region, further addressing its clinical, radiographic, and histological characteristics, with the conservative surgical treatment of choice.

2. Case report

Patient (MNCS), 17 years old, female, Faioderma, from Jequie-BA, attended the Oral and Maxillofacial Surgery Service at the Santo Antonio Hospital: Social Works Irma Dulce Association with a complaint of swelling in the tooth mental region. During anamnesis she reported that the swelling had been present for about 6 months, without pain or bleeding, and it caused a great esthetic deficit (**Figure 1**). The extraoral examination revealed a significant volume increase in the mandible anterior region, while the intraoral examination showed a swelling in the region between the premolars with poor dental positioning of the units involved with an absence of the unit 3.2. On palpation, the lesion had a firm consistency, and the mucosa had normal-looking coloration or feature (**Figure 2**).

Figure 1. Presenting an increase in volume in the mental region

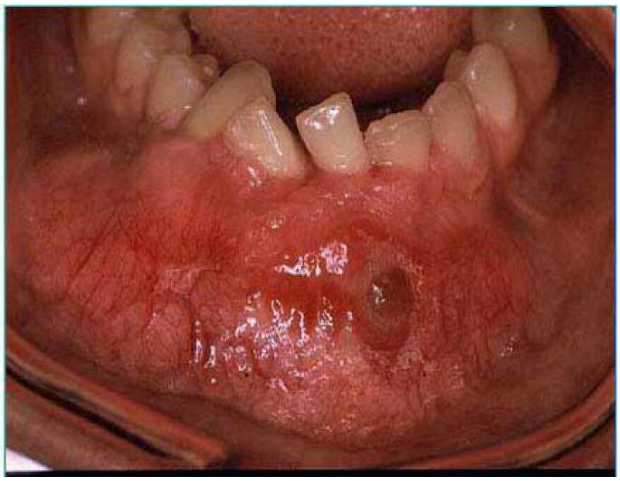

Figure 2. Presents an increase in volume with intra-oral observation

Panoramic and occlusal radiographic exams were performed on the patient, which showed a well delimited radiolucent zone with few radiopaque foci inside, completely involving the dental unit 3.2. It extended from the 1st left pre-molar to the 2nd right pre-molar, and the roots of the units involved were quite divergent and some had resorption processes (**Figure 3**). An incisional biopsy was performed under local anesthesia, together with an aspiration puncture which confirmed the solid nature of the lesion. The histological findings of a cyst wall lined by the proliferation of epithelial cells with central formation of acinar-similar cells with central eosinophilic material and deposition of calcium spherocytes confirmed the diagnosis of AOT, which contradicted the initial clinical suspicion of ameloblastoma, due to the clinical and radiographic features of the lesion.

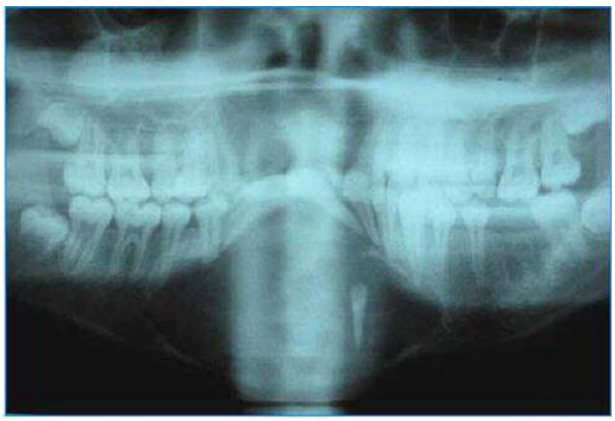

Figure 3. It presents a radiographic view of the Iesao showing the unit 3.2 included

The tumor was removed by curettage, under general anesthesia, followed by verification of the normality as requested by the preoperative. The tumor was encapsulated, which made its complete excision and preservation of the mentonian neurovascular bundles bilaterally. The dental unit 3.2 was removed together with the lesion, and the other units were kept for further endodontic treatment. During the 3-month period, the patient was followed up and there was no report of postoperative discomfort, paresthesia or any sign of the lesion recurrence. The panoramic radiograph of about 100 days after surgery further confirms this clinical finding, and showed a bone neo-formation in the region. The patient continues to follow up, and placed under endodontic treatment for the dental units near the lesion (**Figure 4** and **Figure 5**).

Figure 4. Radiographic aspect showing bone formation observed after 100 days

Figure 5. Facial appearance of the patient at the 100-day return visit demonstrating harmonious facial contour

3. Discussion

The AOT has well defined characteristics, with the highest incidence found in the maxilla. In most of the AOT cases it is associated with retained teeth, and mostly related to canine teeth. The size generally varies between 1.5 to 3 cm, however, there are reports of tumors size of approximately 9 cm [3]. According to the reports, it is generally located in the anterior region of the maxilla, but in this case the lesion was observed in the anterior region of the mandible. It measures in its greatest diameter 0.5 cm, and is associated with an incisor tooth.

There is a predominance of this type of tumor in females, with a 2:1 ratio in female to male, and a greater frequency of incidence is in the second decade of life [2,4,16,20-23]. These mentioned characteristics were found in the present case, in which the patient was female, and 17 years old.

The AOT incidence is more common in the maxilla than in the mandible with a ratio occurrence is 2.1:1 respectively, which differs from the case that is found in our service, as the AOT was presented in the mandible anterior region [2,6]. In most of the cases the radiographic image showed a radiolucent, well defined, circumscribed, unilocular area associated with an unerupted upper canine [8,26], which further differs from the case that is reported here, where it was associated with a lower lateral incisor.

It should be noted that there is no misdiagnosis between AOT and ameloblastoma, because although

both lesions have odontogenic origin, they differ in age, sex, incidence rate, anatomical location, type of treatment and recurrence, and also have distinctive histological aspects [1,4]. In the present study, the presence of large increase in volume, leads to the clinical suspicion of ameloblastoma, however, the incisional biopsy prior to the final treatment revealed the true nature of the tumor, allowing the elaboration of an adequate treatment plan.

AOT is treated surgically by enucleation and curettage, with exclusive removal of the lesion, and with no tendency towards recurrence [4,15,17-19]. In the present case, the surgical approach allowed new formation of the bone in this region, verified by control radiography, as well as the return of the roots that had been found displaced from their initial position.

It is important to report that radiographically it becomes practically impossible in making a precise diagnosis, because it can be confused with a series of other pathologies conditions. The conservative surgical intervention is emphasized as the treatment of choice in cases of adenomatoid odontogenic tumors and the pathological structure, including the affected tooth should be mandatorily sent to histopathological evaluation.

Disclosure statement

The authors declare no conflict of interest.

References

[1] Philipsen HP, Birn H, 1969, The Adenomatoid Odontogenic Tumor; Ameloblastic Adenomatoid Tumor; Or Adenoameloblastoma. Acta Pathol Microbiol Scand, 1969(75): 375.

[2] Philipsen HP, Reichart PA, Zhang KH, 1991, Adenomatoid Odontogenic Tumor: Biologic Profile Based on 499 Cases. J Oral Pathol Med, 1991(20): 149.

[3] Lee JK, Lee KB, Hwang BN, 2000, Adenomatoid Odontogenic Tumor: A Case Report. J Oral Maxillofac Surg, 2000(58): 1161–1164.

[4] Reis SRA, at el., 1991, Tumor Odontogenico Adenomatoide: Relato e um caso (Adenomatoid Odontogenic Tumour: Case Report). Rev. Fac. de Odontologia/UFBA, 1991(10): 11.

[5] Philipsen HP, Reichart PA, Nikai H, 1997, Theadenomatoid Odontogenic Tumour (AOT): An Update. Oral Med Pathol, 1997(2): 55–60.

[6] Philipsen HP, Reichart PA, 1998, Adenomatoidodontogenic Tumor: Facts and Figures. Oral Oncology, 1998(35): 123–125.

[7] Cudney N, Persico J, Cordell KG, et al., 2008, Adenomatoid Odontogenic Tumor Developing in Association with an Odontoma: Report of a Case. Quintessence Int, 39(8): 693–697.

[8] Nonaka CFW, SouZa LB, Quindere LB, 2007, Tumor Odontogenico Adenomatoide Associado a Cisto Dentfgero: Relato de um Caso Incomum (Adenomatoid Odontogenic Tumour Associated with Dentigerous Cyst: Unusual Case Report). Rev Bras Otorrinolaringol, 73(1): 135–137.

[9] Ide F, Mishima K, Saito I, et al., 2008, Rare Peripheral Odontogenic Tumors: Report of 5 Cases and Comprehensive Review of the Literature. Oral Surg Oral Med Oral Pathol Oral Radiol Endod, 106(4): 22–28.

[10] Nigam S, Gupta SK, Chaturvedi KU, 2005, Adenomatoid Odontogenic Tumor: A Rare Cause of Jaw Swelling. BraZ Dent J, 16(3): 251–253.

[11] Santos JN, Lima FO, Romerio P, et al., 2008, Adenomatoid Odontogenic Tumor: An Unusual Case Exhibiting Cribriform Aspect. Quintessence Int, 2008(39): 777–781.

[12] Friedrich RE, Scheuer HA, Zustin J, 2009, Adenomatoid Odontogenic Tumor (AOT) of Maxillary Sinus: Case Report with Respect to Immunohistochemical Findings. In vivo, 23(1): 111–116.

[13] Garg D, Palaskar S, Shetty VP, et al., 2009, Adenomatoid Odontogenic Tumor: Hamartoma or True Neoplasm: A Case Report. J Oral Sci, 51(1): 155–159.

[14] Chuan-Xiang Z, Yan G, 2007, Adenomatoid Odontogenic Tumor: A report of a Rare Case with Recurrence. J Oral Pathol Med, 36(7): 440–443.

[15] Toledo OA, et al., 1994, Tumor Odontogenico Adenomatoide. RGO, 42(1): 31-34.

[16] Ogata DC, Ioshii SO, Sassi LM, et al., 2008, Tumor Odontogenico Adenomatoide Extrafolicular: Uma Apresentaçao Infrequente de um Tumor Raro (Extrafollicular Adenomatoid Odontogenic Tumor: An Unusual Presentation of a Rare Tumor). Rev Bras Cir cabeça PesCoCo, 37(4): 234–235.

[17] Vasconcelos BCE, Silva EDO, Frota R, et al., 2003, Tumor Odontogenico Adenomatoide em Maxila (Adenomatoid Odontogenic Tumour in Maxilla]. Rev Cir Traumat Buco-Maxilo-Fac, 3(3): 15-19.

[18] Vasconcelos BCE, Frota R, Cardoso AB, et al., 2008, Tumor Odontogenico Adenomatoide (Adenomatoid Odontogenic Tumor). Rev Bras Otorrinolaringol, 74(2): 315–318.

[19] Ajagbe HA, Daramola JO, Junaid TA, 1985, Adenomatoid Odontogenic Tumor in a Black African Population: Report of Thirteen Cases. J Oral and Maxillofac Surg, 43(9): 683-687.

[20] Mcguff HS, Alderson GL, Jones AC, et al., 2008, Oral and Maxillofacial Pathology Case of the Month. Adenomatoid odontogenic tumor, Tex Dent J, 125(12): 1192–1195.

[21] Silva MS, Freire EG, Anjos ED, et al., 2004, Tumor Odontogenico Adenomatoide: Relato de Caso CrniCo (Adenomatoid Odontogenic Tumor: A Case report). Rev Cir Traumatol Buco-maxilo-fac, 4(4): 246–251.

[22] Swasdison S, DhanuthaI K, Jainkittivong A, et al., 2008, Adenomatoid Odontogenic Tumors: An Analysis of 67 Cases in a Thai Population. Oral Surg Oral Med Oral Pathol Oral Radiol Endod, 105(2): 210–215.

[23] Botelho TL, Araujo MBG, Bueno TS, et al., 2005, Tumor Odontogenico Adenomatoide: Relato de Caso CrniCo (Adenomatoid Odontogenic Tumor: Report of Case). Rev Bras Patol Oral, 4(3): 177–181.

[24] Borges SP, Santos LAN, Paula AMB, et al., 2005, Tumor Odontogenico Adenomatoide (Adenomatoid Odontogenic Tumor). Rev Bras Odontol, 62(1/2): 113–114.

[25] Stafne EC, 1948, Epithelial Tumors Associated with Developmental Cysts of the Maxilla: Report of 3 cases. Oral Surg, 1948(1): 887.

Publisher's note

Bio-Byword Scientific Publishing remains neutral with regard to jurisdictional claims in published maps and institutional affiliations.

Oncology Treatment Discovery, 2023, Volume 1, Issue 1
http://ojs.bbwpublisher.com/index.php/OTD

Biomarkers of Acute Appendicitis Severity: Diagnostic Test Study

Ledmar J Vargas–Rodriguez[1]*, Jonathan F Barrera–Jerez[2,3], Kelly A Avila–Avila[2,3], David A Rodriguez–Mongui[1], Brayan R Munoz–Espinosa[1]

[1]University of Boyacá, Tunja, Boyacá, Colombia

[2]Pedagogical and Technological University of Colombia, Tunja 150003, Boyacá, Colombia

[3]Regional Hospital of Orinoquia ESE, Yopal 850002, Casanare, Colombia

Corresponding author: Ledmar J Vargas–Rodriguez, lejovaro@gmail.com

Copyright: © 2023 Author(s). This is an open-access article distributed under the terms of the Creative Commons Attribution License (CC BY 4.0), permitting distribution and reproduction in any medium, provided the original work is cited.

Abstract: Appendicitis (AA) is one of the most frequent abdominal surgical pathologies in the world, with appendectomy being the most frequently performed emergency surgery worldwide. This study was conducted to determine the possible biomarkers to detect the severity in AA for diagnostic purposes, and for the timely management of appendicitis and, thereby avoiding possible complications. This research was conducted based on a randomized sampling, where a total of 239 patients diagnosed with AA at the Hospital Regional de Orinoquia, Colombia was recruited for this study. Blood count, C–reactive protein (CRP), and neutrophil/lymphocyte ratio (NLR) records were analyzed, further their relationship with the surgical findings of AA described by Guzman–Valdivia was established. The study showed that, in the emergency department, these reactants are capable of making an approximate diagnosis and as biomarkers of the severity of AA, with CRP>15mg/dL (diagnostic accuracy 76.15%), and the percentage of neutrophils>85% (diagnostic accuracy 61.09%) being the best initial operative performance. For complications, such as intestinal perforation, CRP>15mg/dL and neutrophil percentage>85% were found statistically to be the biomarkers with the highest predictive performance, with OR 14.46, and OR 2.17, respectively, which is consistent with the findings described by Guzman–Valdivia. In conclusion, elevated level of CRP and neutrophil percentage>85 is the acute phase reactants with the best diagnostic characteristics and predictors of possible complications of AA.

Keywords: Appendicitis; Perforation; Biomarkers; Severity; Acute appendicitis

Online publication: April 19, 2023

1. Introduction

Appendicitis is defined as an inflammation of the vermiform appendix, which is the most common (approximately 60% of total appendicitis) symptoms of acute abdominal. Therefore, appendectomy is the most commonly performed emergency surgery globally [1-4]. It has been estimated that the lifetime risk of developing this disease is approximately 12% [2,3,5], with young people under 29 years of age accounted of 45% from the total appendicitis patients [4,6–9].

This pathology occurs due to inflammation of the cecal appendix, secondary to obstruction of its lumen by faecaliths, lymphoid hyperplasia, tumors, parasites, and others. This condition will disrupt the local blood flow, irritating the adjacent peritoneum, subsequently causing pain. This eventually leads to perforation of the anatomical structure with the release of intestinal contents into the abdominal cavity,

resulting in complications such as peritonitis, sepsis, shock, and in some severe cases can cause death [10–12].

To avoid the completion, therefore it is important for the earlier clinical picture and the pathology identification. However, the diagnosis process becomes late due to the great variety in the presentation of the disease between different individuals, age groups, and genders. In addition, the symptoms of appendicitis are not very specific, thereby often lead to misdiagnosis or late diagnosis in up to 1 in 5 patients [13–17].

In order to achieve a timely diagnosis and decrease the complication rate in patients with the abdominal pain, the clinical component and diagnostic tests (paraclinical) should be combined during the diagnosis procedure, thereby reducing the misdiagnosis or late diagnosis by an estimated 5% to 22%, representing a cost reduction of up to 200,000 Euros per year [18]. This is why a number of scales have been developed in an attempt to help the clinician to recognize which patients with abdominal pain is most likely to suffer from this disease. Among the available scales are the Alvarado scale, the pediatric appendicitis score (PAS), and the RIPASA score, where all the scores are correlated to the clinical manifestations, followed by incorporation of laboratory test results during the diagnosis process [18–21]. However, there is no biomarker with optimal performance, which can independently and effectively diagnose acute appendicitis (AA) or can predict severity or complications of the disease [19–21].

The aim of this article is to analyze the biomarkers which can be used to estimate the severity of the AA during the diagnostic purposes, and for timely management in the emergency department surgical disease diary.

2. Materials and methods

2.1. Population

The universe of the study was the entire population with a diagnosis of AA, which were identified by using the international disease code (ICD–10) as follows: K37: Appendicitis; K35.9: Acute catarrhal, fulminant, gangrenous, obstructive, retrocecal, and suppurative appendicitis; K35.1: AA with peritoneal abscess; K35.0: AA, perforation, peritonitis or rupture; A06.8: Amoebic appendicitis; and K36: Obstructive appendicitis, who attended the Hospital Regional de la Orinoquia (HORO) in Yopal between January 1, 2013 to December 31, 2018.

The following variables were taken into account to calculate the study sample size: The population attended according to the clinical records of the institution was 760 people who were diagnosed with appendicitis, the prevalence of appendicitis is 24.6% [22], margin of error of 5% and 95% confidence interval (95% CI), therefore 239 people were included in this study, which were selected by simple random probability sampling.

2.2. Inclusion criteria

The population seen at the HORO from 2013 to 2018 with a score on the Alvarado scale [22] was included. A score of 5 to 6 is compatible with a diagnosis of AA, 7 to 8 indicates probable appendicitis, and 9 to 10 indicates very probable appendicitis, together with an imaging study of ultrasound or tomography and histopathological study to further confirm the diagnosis. In addition, the patient has to present the Guzman–Valdivia scale according to the intraoperative findings.

2.3. Exclusion criteria

Medical records with incomplete or non–existent blood count (or CBC), C–reactive protein (CRP), neutrophil/leukocyte ratio (NLR), and patients under 18 years of age were excluded from this study.

2.4. Variables

Based on the study conducted by Calvo et al., [23] a list of variables was established for this study, including:

(1) Socio–demographic: Sex, age, rural, or urban origin
(2) Clinical parameters: Acute epigastric pain radiating to the right iliac fossa and fever
(3) Paraclinical data: White blood cell count greater than 11,000, neutrophil percentage>85%, lymphocyte percentage>10%, INL greater than 5.5, and CRP greater than 15mg/dL.

2.5. Statistical analysis

The collected information was recorded in Excel, version 2013, and analyzed in the SPSS statistical software, version 22. The univariate analysis was performed by means of descriptive statistics for the selected population, and the absolute and relative frequencies were determined for categorical variables. In the case of quantitative variables, measures of central tendency (mean, median) and of dispersion (standard deviation and interquartile range) were calculated, according to the distribution of the variable.

The cutoff values for leukocyte count (>11,000/mm^3), neutrophil percentage (>85%), lymphocyte percentage (>10%), CRP (>15mg/dL), and INL (>5.5) were used to differentiate between severe and uncomplicated cases, and the cutoff values were determined using receiver operating characteristics (ROC) curve by means of SPSS software. Finally, to determine the possible associations between the categorical variables, tetrachoric tables were made with measurement of the diagnostic Odds Ratio with their respective 95% CI [<1: As a predictor of mild severity or without perforation; >1: As a predictor of severe severity (perforation); and =1: With no association]. Additionally, the operative characteristics of the analyzed paraclinical tests were estimated to determine the operative characteristics of the different diagnostic tests (sensitivity, specificity, positive predictive value, and negative predictive value), which are most frequently performed during hospitalization of the patients with AA.

2.6. Bias

This study considered to have a low risk of bias, since the scale used as a reference method (Guzman and Valdivia) is based on the findings during the surgical procedure, which are classified into 4 grades; 0: No appendicitis (prophylactic appendicitis, no post–surgical antimicrobial scheme); Ia: Oedematous and ingurgitated; Ib: Abscessed or phlegmonous (with seropurulent fluid around the appendix); Ic: Necrotic without perforation; II: Perforated with localized abscess; III: Complicated appendicitis with generalized peritonitis). The usage of this scale maintains a low risk of error in addition to the dichotomization of the same, in order to assess severity. The qualitative variables were taken as dichotomous in order to facilitate the analysis, and to perform an adequate calculation of the operational characteristics, which will further facilitate the assessment and grouping of the participants.

2.7. Ethical considerations

Based on the resolution 8430 of 1993, it was considered a free-risk study, as the study was conducted based on the review of medical records. In addition, the appropriate permissions were requested from the institution in charge of the custody of the medical records.

3. Results

A total of 239 patient records with diagnosed with AA were evaluated, and the process for choosing the appropriate study sampling were shown as in **Figure 1**.

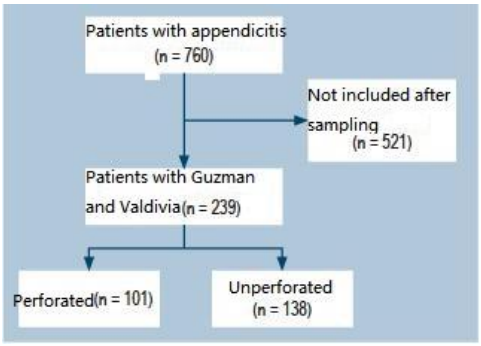

Figure 1. Process for patient recruitment and selection according to sample size

3.1. Socio-demographic characterization

The mean age of the population was 26.35 years, SD ± 6.4 years (coefficient of variation 24%), with a minimum of 18 years and a maximum of 46 years. **Table 1** shows the characteristics of the population.

Table 1. Population characteristics

Variable	N	%	IC95%	
Sex				
–Female	127	53	46.81	59.46
–Male	112	47	40.54	53.19
Residence				
–Urban	155	64.8536	65.21	79.31
–Rural	84	35.1464	29.09	41.2
Grade according to the Guzman-Valdivia scale				
–1a	65	27.1967	21.56	32.84
–1b	51	21,3389	16.15	26.53
–1c	22	9.20502	5.54	12.87
–2	32	13.3891	9072	17.71
–3	69	28.8703	23.13	34.62

Regarding the characteristics of the inflammatory reactants, the mean value of the leucocyte count was 15,512.2/mm^3 with an SD ± 5,386.84/mm^3 (minimum 1,904.1/mm^3; maximum 32,000/mm^3). The neutrophil percentage averaged was 12.625 with SD ± 5,338.36/mm^3 (minimum 1,294.72/mm^3; maximum 27,840/mm^3). Lymphocytes had a mean value of 2,271.28/mm^3 with SD ± 2,125.6/mm^3 (minimum 443/mm^3 and maximum 17,908/mm^3). Meanwhile, the INL averaged was 8.5 with an SD ± 6.8 (minimum of 1 and maximum of 31). The CRP averaged was 47.46 mg/dL with an SD ± 60.7 mg/dL (minimum of 0.50 mg/dL and maximum of 316 mg/dL).

A ROC curve was performed to determine the most accurate cutoff point for each of the variables, and the following values were found from the ROC curve: Leukocyte count>11,000/m^3; percentage of neutrophils>85%; CRP>15mg/dL; percentage of lymphocytes>10%; and INL>5.5 as shown in **Figure 2**.

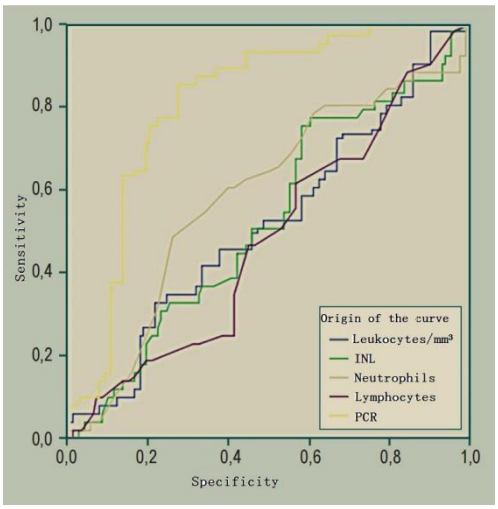

Figure 2. ROC curve

3.2. Diagnostic tests

In total, 101 persons had severe degrees of appendicitis, meaning that around 42.2% of total appendicitis persons had an appendiceal perforation. The results indicate that patients with a neutrophil percentage>85% are 2 times more likely to have intestinal perforation, while patients with CRP>15mg/dL are 14 times more likely to have this complication (**Table 2**).

Table 2. Tetrachoric table between paraclinicals with histopathology

Paraclinical	Acute appendicitis		OR	IC 95%
	Perforated (n=101)	Unperforated (n=138)		
Leukocyte count than 11,000	79	107	1.04	0.56; 1.93
	22	31		
Percentage of neutrophils>85%	55	47	2.17	1.28; 3.66
	46	91		
Percentage of lymphocytes>10%	68	93	0.99	0.57; 1.72
	33	45		
INL>5.5	62	78	1.22	0.82–1.52
	39	60		
PCR>15mg/dL	88	44	14.46	7.3; 28.6
	13	94		

3.3. Characteristics of diagnostic tests

Interestingly, it was found that the tests with the highest ability to detect people with appendiceal perforation (sensitivity) were CRP and leukocyte count greater than 11,000/mm^3, with data of 87.13% and 78.22%, respectively (**Table 3**).

The tests with the best ability to detect persons with a non–perforated appendix (specificity) were CRP and the percentage of neutrophils>85%, with 68.12% and 65.94%, respectively (**Table 3**). Finally, the test with the highest diagnostic accuracy was CRP with 76.15% (**Table 3**).

Table 3. Characteristics of diagnostic tests

Operational characteristics	Leukocytes	Neutrophils	Lymphocytes	INL	PCR
Sensitivity	78.22%	54.46%	67.33%	61.39%	87.13%
Specificity	22.46%	65.94%	32.61%	43.48%	68.12%
Positive predictive value	42.47%	53.92%	42.24%	44.29%	66.67%
Negative predictive value	58.49%	66.42%	57.69%	60.61%	87.85%
Diagnostic accuracy	46.03%	61.09%	47.28%	51.05%	76.15%
Likelihood ratio of the positive test	1009	1599	0.999	1086	2733
Likelihood ratio of the negative test	0.9697	0.6907	1002	0.8881	0.189

4. Discussion

In the present study, the population studied represents a relatively young population, with an average age of 26.35 years, which allows a comparison with epidemiological data from other studies, such as the research conducted by of Canovas et al., and Escalona et al., where the average age at presentation of appendicitis was 21 and 29 years, respectively [24,25]. This allows us to find no significant difference in the results obtained. However, this study in contrast with the study conducted by Jonge et al., which had an average age of 55 years [26].

On the other hand, the majority of people diagnosed with AA were women, 53% of the total population, consistent with the results shown in other publications, such as that of Jonge et al., [26], in which the base population was female with 51.2%. However, in another study the majority of patients are male, for example study conducted by Padierna and colleagues, in which it was 50.81% [27]. However, there are no significant differences in terms of gender with regard to the occurrence of AA. Although, it is important to mention that the female gender is more difficult to diagnose, especially during childbearing age or pregnancy, as this characteristic could lead to a confusion at the time of diagnosis [28,29]. Another important feature is that more patients come from the urban areas, than rural areas.

It should be taken into account that the numerous studies documents that the pathophysiological stages of appendicitis can be divided into three groups, with respect to the time of clinical evolution: Incipient: 0–12 hours; Acute: 12–24 hours; and Perforated: 24–48 hours [1,4,10].

In this study, we did not look for the relationship between clinical evolution and the presence of perforation, however, we investigated the comparison of the results of the different stages according to the Guzman–Valdivia classification [30], which indicates that the higher the grade, the greater the severity of the disease, and by using the research of Martinez and collaborators [31], in which the following results were obtained in the present study: Grade 0: 4 patients; Grade 1A: 26 patients; Grade 1B: 32 patients; Grade 1C: 27 patients; Grade 2: 22 patients; and Grade 3: 11 patients, for a total of 122 patients.

From these results we found that the percentages were higher in our investigation, with a percentage difference in grades 1A (5.88%) and 3 (19.96%), which indicates that the most serious complication is perforation with generalized peritonitis occurred more frequently in this study. Where, in other studies conducted by Rigual et al., [19] and Beltran et al., [4], the perforation was found to have a prevalence of 10% and 24%, respectively which is still low compared to our study where we obtained a prevalence of 42.25% in perforations.

With regard to inflammatory reactants, leukocytosis and neutrophilia were found to be associated with the diagnosis of AA. According to the results obtained in this study, having a neutrophil percentage>85% increases the likelihood of an outcome of appendiceal perforation (OR 2.17; 95% CI 1.28–3.66) as shown in **Table 2**. Similarly, an NLI greater than 5.5 which is above baseline was found in patients diagnosed with AA (OR 1.22; 95% CI 0.82–1.52).

It is noteworthy that patients with AA were found to have a significant CRP positivity (47.46mg/dL). Statistical analysis showed in this study, the population with a CRP>15 mg/dL showed a statistically significant OR (OR 14.46, 95% CI 7.3–28.5; 1.5); 95% CI 7.3–28.6), which is parallel with other publications regarding the usefulness of this biomarker as a diagnostic aid. For example, a study conducted by Ishizuka et al., who analyzed the relationship of INL with gangrenous and perforated appendicitis in 314 patients, establishing a figure of 8 as the cutoff point, with a sensitivity and specificity of 73% and 39%, respectively [32], with results lower than those of our study.

Therefore, based on the results obtained from the present study, the diagnostic tests with the best operational performance in the emergency department in a patient suspected with AA are CRP (sensitivity: 87.13%; specificity: 68.12%; diagnostic accuracy: 76.15%), and the percentage of neutrophils>85% (sensitivity: 54.46%, specificity: 65.94%, diagnostic accuracy: 61.09%). These results are similar to previous studies conducted by Aguirre and colleagues, where they showed a similarity in the relationship between CRP, eosinophilia, and pathology [28]. Overall, the results provide us with valuable tools for daily clinical practice, however, we believe that there is a greater need for further research in this field to achieve uniformity of information on a national basis, and to obtain tools that will allow us to address issues such as AA at an earlier stage.

The study by Padierna et al., compared only CRP and white blood cell count as predictors of severity, obtaining a sensitivity of 98.3% and specificity of 88.9% for CRP, and a sensitivity of 80% and specificity of 61% for white blood cell count [27]. This makes it possible to determine that the results obtained are consistent with this research in terms of PCR value, but there is a significant difference with respect to the results of the leucocyte count, since a sensitivity of 78.22% and specificity of 22.46% was obtained, with a diagnostic accuracy of 46.03%. This determines that the results are totally unequal in this study, and that this leucocyte count should not be used as one of the pillars for determining prognosis in the emergency department, due to its low specificity.

This is also seen in the study by Acharya et al., where CRP was evaluated with a sensitivity of 75% and specificity of 50% and the leucocyte count with a sensitivity of 79% and specificity of 55%, as well as other paraclinicals such as bilirubin, procalcitonin, IL-6, and urinary serotonin, as other diagnostic and prognostic factors for AA [29]. In this case, the leucocyte count had a higher value than CRP, which is a notable difference based on the results obtained, as well as in relation to the rest of the literature reviewed. These results could perhaps be explained by the multiple limitations in the study, as well as potential sources of bias due to blinding of the researchers in the literature reviewed.

It is important to note that according to the study conducted by Prasetya et al., the NLI had a high diagnostic accuracy for AA in children, with sensitivity percentages of 84.6% and specificity of 56.5%, which are higher than those obtained in our study of 61.39% and 43.48%, respectively. This is probably due to the difference in the age of the study population, since the maximum age in the study was 18 years, and also to the fact that this is a retrospective study, which is a limitation that should be considered when taking into account when interpreting the results [33].

5. Conclusions

Currently, AA remains a challenge for both diagnosis and prognosis in the emergency department, both for the general practitioner and the specialist, because there is still no biomarker to define how advanced the disease is and what its possible complications are. However, this study was able to determine the operational characteristics of inflammatory reactants as a predictor of severity in AA, and thus prevent possible complications. CRP was found to have the highest specificity and sensitivity, and was also the most positive OR predictor compared to the other reactants.

Similarly, it was found that a white blood cell counts greater than 11,000/mm^3 and a neutrophil

count >85% were associated with the diagnosis of AA. In addition, according to the results obtained in this study, a neutrophil percentage>85% increases the likelihood of a complication of the condition (OR 2.17), while a CRP greater than 15mg/dL increases the likelihood of a complication of the condition (OR 14.46). This could be a definitive characteristic for finding the likelihood of complications in AA in any age group.

In conclusion, this study allowed us to determine the cutoff points for paraclinical variables widely used to predict and prevent complications of AA, such as perforation, which would allow us to optimize in-hospital management, which would ultimately have an impact on final care costs, further shorter the patient recovery time.

Disclosure statement

The authors declare no conflict of interest.

References

[1] Bahena-Aponte JA, Chavez-Tapia NC, Mendez-Sanchez N, 2003, Estado Actual de la Apendicitis (Current Status of Appendicitis). Med Sur, 2003(10): 122–128.

[2] Huacuja-Blanco RR, Ruiz-Campos M, Lemus-Ramirez RI, et al., 2015, Factores Predictores Para Apendice Blanca y Apendicitis Aguda en Pacientes Sometidos a Apendicectomia. Experiencia de dos Anos en una Institucion Privada (Predictors of White Appendix and Acute Appendicitis in Patients Undergoing Appendectomy. Two-year Experience in a Private Institution). Med Sur, 2015(22): 11–18.

[3] Benito J, Fernandez S, Gendive M, et al., 2020, A New Clinical Score to Identify Children at Low Risk for Appendicitis. Am J Emerg Med, 2020(38): 554–561.

[4] Beltran MA, Almonacid FJ, Vicencio A, et al., 2007, Rol del Recuento de Leucocitos y de la Proteina C Reactiva en Ninos Con Apendicitis (Role of Leukocyte Count and C-Reactive Protein in Children with Appendicitis). Rev Chil Cir, 2007(59): 38–45.

[5] Cuervo JL, 2014, Apendicitis Aguda (Acute Appendicitis). Rev Hosp Ninos, 2014(56): 15-31.

[6] Alarcon Thompson N, 2012, Asociacion entre Escala de Alvarado y Diagnostico de Apendicitis Aguda Complicada y no Compli-Cada Segun Anatomia Patologica en el Centro Medico Naval (Association between Alvarado Scale and Diagnosis of Complicated and Uncomplicated Acute Appendicitis According to Anatomical Pathology at the Naval Medical Centre). Rev Horiz Med (Barcelona), 2012(12): 14–20.

[7] Rebollar RC, Alvarez JG, Tellez RT, 2009, Apendicitis Aguda: Revision de la Literatura (Acute appendicitis: A review of the literature). Rev Hosp Jua Mex, 2009(76): 210–216.

[8] Fallas J, 2012, Apendicitis Aguda (Acute Appendicitis). Med Leg Costa Rica, 2012(29): 83–90.

[9] Aila MJ, Garcia-Acero M, 2015, Apendicitis Aguda: Revision de la Presentacion Histopatologica en Boyaca, Colombia (Acute Appendicitis: A review of Histopathological Presentation in Boyaca, Colombia). Rev Colomb Cir, 2015(30): 125–130.

[10] Hernandez-Cortez J, De Leon-Rendon JL, Martinez-Luna MS, et al., 2019, Apendicitis aguda: Revision de la Literatura (Acute Appendicitis: A Review of the Literature). Cir Gen, 2019(41): 33–38.

[11] Rodriguez-Fernandez Z, 2018, Consideraciones Vigentes en torno al Diagnostico de la Apendicitis Aguda (Current Considerations in the Diagnosis of Acute Appendicitis). Rev Cuba Cir, 2018(57): 55–71.

[12] Rodriguez-Fernandez Z, 2009, Consideraciones Actuales Sobre el Diagnostico de la Apendicitis Aguda (Current Considerations in the Diagnosis of Acute Appendicitis). Rev Cuba Cir, 48: 1–9.

[13] Calvo-Hernandez LD, 2012, Apendicitis Aguda en el Servicio de Urgencias (Acute Appendicitis in the Emergency Department). Rev Med Cos Cen, 2012(69): 281–285.

[14] Udaquiola J, Arriaga V, Oesterreich R, et al., 2014, Apendicitis Aguda (Acute Appendicitis). Rev Pediatr Elizalde, 2014(5): 44–46.

[15] Sanabria A, Dominguez LC, Vega V, et al., 2013, Tiempo de Evolucion de la Apendicitis y Riesgo de Perforacion (Time Course of Appendicitis and Risk of Perforation). Rev Colomb Cir, 2013(28): 24–30.

[16] Fernandez MG, Costa Marsicano JM, 2018, Apendicitis Aguda y sus Complicaciones [Acute Appendicitis and its Complications]. Clin Quir Fac Med UdelaR, 2018: 1–7.

[17] Souza-Gallardo LM, Martinez-Ordaz JL, 2017, Apendicitis Aguda. Manejo Quirurgico y no Quirurgico (Acute Appendicitis. Surgical and Non-surgical Management). Rev Med Inst Mex Seguro Soc, 2017(55): 76–81.

[18] Sanchez-Echaniz J, Garcia L, Vazquez–Ronco MA, et al., 1998, Valor diagnostico de la Proteina C reactiva en las Sospechas de Apendicitis Aguda en la Infancia (Diagnostic Value of C-Reactive Protein in Suspected Acute Appendicitis in Childhood). An Esp Pediatr, 1998(48): 470–474.

[19] Calvo-Rigual F, Sendra-Esteve S, Mialaret-Lahiguera A, 1998, Valor de la Proteina C-Reactiva en el Diagnostico de la Apendicitis Aguda en el Nino (Value of C-Reactive Protein in the Diagnosis of Acute Appendicitis in Children). An Esp Pediatr, 1998(48): 376–380.

[20] Prada-Arias M, Salgado-Barreira A, Montero–Sanchez M, et al., 2018, Apendicitis Versus Dolor Abdominal Agudo Inespecifico: Evaluacion del Pediatric Appendicitis Score (Appendicitis Versus Non-Specific Acute Abdominal Pain: Evaluation of the Pediatric Appendicitis Score). An Pediatr, 2018(88): 32–38.

[21] Neira-Sanchez ER, Malaga G, 2016, Sepsis-3 Y Las Nuevas Definiciones, es Tiempo de Abandonar SIRS? (Sepsis-3 and the New Definitions, is it Time to Abandon SIRS?) Acta Med Peru, 2016(33): 217–212.

[22] Alvarado A, 1986, A Practical Score for the Early Diagnosis of Acute Appendicitis. Ann Emerg Med, 1986(15): 557–564.

[23] Calvo-Rodriguez R, Gallardo-Valverde JM, Montero-Perez FJ, et al., 2016, Utilidad de los Biomarcadores en el Manejo del Dolor Abdominal (Utility of Biomarkers in Abdominal Pain Management). Rev Cient Soc Esp Med Urg Emerg, 2016(28): 185–192.

[24] Canovas VN, Vera FM, Candia CR, et al., 2003, Proteina C Reactiva Como Predictor de Complicaciones Postoperatorias en Apendicitis Aguda (C–Reactive Protein as a Predictor of Postoperative Complications in Acute Appendicitis). Rev Chil Cir, 2003(55): 628–630.

[25] Escalona PA, Bellolio RF, Dagnino UB, et al., 2006, Utilidad de la Proteina C Reactiva y RECUENTO de Leucocitos en Sospecha de Apendicitis Aguda (Usefulness of C-Reactive Protein and Leukocyte Count in Suspected Acute Appendicitis). Rev Chil Cir, 2006(58): 122–126.

[26] De-Jonge J, Bolmers MDM, Musters GD, et al., 2019, Predictors for Interval Appendectomy in Non–Operatively Treated Complicated Appendicitis. Int J Colorectal Dis, 2019(34): 1325–1332.

[27] Padierna-Luna JL, Ruiz-Valenzuela KL, Morales-Arellano AC, 2005, Proteina C Reactiva en el Diagnostico de Apendicitis Aguda (C-Reactive Protein in the Diagnosis of Acute Appendicitis). Rev Mex Patol Clin Med Lab, 2005(52): 163–167.

[28] Aguirre GA, Falla A, Sanchez W, 2014, Correlacion de los Marcadores Inflamatorios (Proteina C Reactiva, Neutrofilia y Leucocitosis) en las Diferentes Fases de la Apendicitis Aguda [Correlation of

Inflammatory Markers (C-Reactive Protein, Neutrophilia and Leukocytosis) in the Different Phases of Acute Appendicitis]. Rev Colomb Cir, 2014(29): 110–115.

[29] Acharya A, Markar SR, Ni M, et al., 2017, Biomarkers of Acute Appendicitis: Systematic Review and Cost–Benefit Trade–Off Analysis. Surg Endosc, 2017(31): 1022–1031.

[30] Guzman-Valdivia Gomez G, 2003, Una Clasificacion Util en Apendicitis Aguda (A Useful Classification in Acute Appendicitis). Rev Gastroenterol Mex, 2003(68): 261–265.

[31] Martinez-Luna MS, Guzman-Ortiz JD, Ruschke-Sadot G, 2015, Uso de Proteina C Reactiva (PCR) Como Predictor de Complicaciones en Apendicitis Aguda (Use of C–Reactive Protein (CRP) as a Predictor of Complications in Acute Appendicitis). Rev Mex Cirug Apar Diges, 2015(4): 100–103.

[32] Ishizuka M, Shimizu T, Kubota K, 2012, Neutrophil-to-Lymphocyte Ratio has a Close Association with Gangrenous Appendicitis in Patients Undergoing Appendectomy. Int Surg, 2012(97): 299–304.

[33] Prasetya D, Rochadi, Gunadi, 2019, Accuracy of Neutrophil Lymphocyte Ratio for Diagnosis of Acute Appendicitis in Children: A Diagnostic Study. Ann Med Surg (Lond), 2019(48): 35–38.

Publisher's note

Bio-Byword Scientific Publishing remains neutral with regard to jurisdictional claims in published maps and institutional affiliations.

Oncology Treatment Discovery, 2023, Volume 1, Issue 1
http://ojs.bbwpublisher.com/index.php/OTD

PET/CT in Staging and Treatment Evaluation of Non-Small Cell Lung Cancer

Rosanna Elvira Morales Guzmán-Barrón[1]*, Edgar Amorín Kajatt[2], Richard Ledesma Vásquez[1], Sandro Casavilca Zambrano[3]

[1]Department of Nuclear Medicine, National Institute of Neoplastic Diseases, Surquillo 15038, Lima, Peru

[2]Department of Thoracic Surgery National Institute of Neoplastic Diseases, Surquillo 15038, Lima, Peru

[3]Department of Pathology, National Institute of Neoplastic Diseases, Surquillo 15038, Lima, Peru

Corresponding author: Rosanna Elvira Morales Guzmán-Barrón, rmoralesgb@gmail.com

Copyright: © 2023 Author(s). This is an open-access article distributed under the terms of the Creative Commons Attribution License (CC BY 4.0), permitting distribution and reproduction in any medium, provided the original work is cited.

Abstract: Lung cancer relatively common in Peru. PET/CT is a useful tool in the staging and follow-up of the treatment of lung tumors. There is currently enough evidence to affirm that this technology helps in adjusting treatment and increasing the survival rate of the patients. A descriptive review of the relevant articles recently published on the subject was carried out. It is concluded that PET/CT is useful in the staging and follow-up of the proposed treatment for patients with non-small cell lung cancer. This malignant tumor is also often discovered and diagnosed at an advanced stage.

Keywords: Non-small cell lung cancer; PET/CT; Treatment; Non-invasive surgery; Radiomics; Computed tomography

Online publication: May 17, 2023

1. Introduction

Approximately 80-85% of lung neoplasms are non-small cell tumors, with the main types being adenocarcinoma, squamous cell carcinoma and large cell carcinoma [1,2]. They are grouped together because they behave similarly and respond in the same way to treatment. According to the latest statistical reports, non-small lung tumors have the highest mortality rate in the world [3], with an overall survival rate of 17.4%. In Peru, it occupies third place in incidence and fifth place in frequency in Peru, among all types of malignant neoplasms [4].

Non-small cell lung cancer occurs equally in men and women, is aggressive, and has a higher mortality rate, mainly due to the fact that the diagnosis is made in advanced stages, and it continues to spread [5]. The proportion of new cancer cases diagnosed in less developed countries is expected to increase more than 60% of the world total by 2030, due to increase in cancer rates and expected increases in life expectancy and population growth. Only 10% of stage IV patients exceed 60 months of survival after diagnosis.

Positron emission tomography linked to tomography (PET/CT) is important to the precision medicine in patients with lung cancer, and it is crucial for optimal patient management and determining initial staging. The therapeutic approach of about one third of lung cancer patients was changed after evaluation with PET/CT. This allows an appropriate re-staging of the disease, detection of residual disease and its recurrence; it also evaluates the therapeutic response and aids the patient's prognosis [6].

PET/CT is also important in the planning of radiotherapy by determining the extent of active disease and functional tumor volume [7]. Recent advances suggest that therapeutic response criteria in the near

future will be based on metabolic characteristics and will include assessment of the biological characteristics of tumors to further improve the efficacy of precision medicine in lung cancer, thus producing better patient outcomes with less morbidity [8].

Therefore, PET/CT should be highlighted so that a more accurate diagnosis can be made, the extent of disease (staging) can be better assessed, and a more suitable follow-up treatment can be selected for a given patient.

2. Methodology of the literature search

Databases (PubMed, Elsevier, Scopus, Cochrane Reviews, Google Scholar) were consulted, and original articles related to non-small cell lung cancer were reviewed. In addition, we also searched for papers that clarifies some issues of staging of non-small cell lung cancer and positron emission tomography technology (PET/CT).

3. Establishment of the search strategy

The keywords used were PET/CT, NSCLC, staging, non-small cell lung cancer, non-invasive therapy, thoracotomy, mortality, response to treatment, radiotherapy, and chemotherapy.

Articles that were published in the last ten years were included in this paper, including some older articles because of their importance and relevance. Studies with less than 20 patients were so that this review will be more relevant.

4. Selection of results

We selected original articles that involved the use of PET/CT in the initial diagnosis and staging of non-small cell lung cancer and those that had information on the patients' follow-up after treatment.

Eighteen articles that met the selection criteria: title related to the topic, clear and specific summary of the study topic, relevant results, study delimitation statement and appropriate number of cases, (including two meta-analyses) were reviewed, in addition to multicenter studies. An additional 5 studies that provided statistical data or general concepts to clarify the review topic were also included in this review.

The results of the studies reviewed, which adequately measure the effect of using PET/CT in non-small cell lung cancer, at various stages, with various treatments, such as curative or palliative surgery, chemotherapy or radiotherapy in different modalities were reliable. The reliability was determined based on the soundness of the work and the methodology used.

5. Development of the topic

A descriptive review was carried out on the literature we compiled. Some authors such as Farsad [2] say that PET/CT cannot determine the parameters of the tumor although it is very useful in determining the nodal involvement and predicting the outcome of treatment. Fischer [1] stated that there was no significant contribution in the evaluation of nodal involvement, an aspect in which progress has been made in the last decade.

The staging of non-small cell lung cancer is a multidisciplinary process that involves a set of imaging studies and endoscopic and surgical components [9]. PET/CT studies are non-invasive and have been shown to have a relevant negative predictive value, which makes invasive studies unnecessary for the evaluation of mediastinal nodes. In the case of being positive, it requires the other studies for its confirmation. There are authors who recommend using PET/CT, CT, and invasive studies altogether to achieve an adequate staging [10–15].

6. Preoperative staging

There is a previous review of the subject carried out in 2015 by Hochhegger *et al.* [16], in which they schematize the TNM methodology to evaluate the usefulness of PET/CT in evaluating tumors (T), lymph nodes (N) and metastases (M).

In other studies, such as the meta-analysis performed by Zhao et al [17], the study of the nodal component (N) in the mediastinum and in other locations has been shown to be more precise. This study confirms that PET/CT has good specificity but lacks sensitivity.

A study carried out by Osman and Korashi [18] in the year 2020 stated that PET/CT is most useful in reviewing the T component, is when performing staging of patients with T2 (using the nomenclature of the 8th version of the TNM that is currently in force) [19]; a tumor stage in which it allows elucidation of the tumor region of the adjacent inflammatory region.

This same finding has been found in another publication [20], in which De Cecco and coworkers studied the inflammatory involvement around the primary tumor, before and after radiotherapy.

There is a study on the evaluation of the metabolic parameters of PET-CT (total tumor volume, SUV_{max}, total glycolysis of the lesion) in determining whether a patient has second primary synchronous or metachronous tumors following non-small cell lung cancer, which is relatively common [21]. Zhu *et al.* [22] mentioned that these parameters can be used to predict the overall survival of the patient with acceptable accuracy regardless of age, type of treatment, tumor histology and TNM stage.

Similar observations were found in a study by Dashevsky *et al* [23], who reported what was found in a T3B stage, specifically in non-small cell lung cancer; they concluded that the total tumor volume marker is a prognostic marker of stage 3B of the neoplasm, regardless of age, gender, treatment or tumor histology.

Artificial intelligence plays a role in imaging studies. Borreli *et al* [24] studied the use of artificial intelligence in the management of patients with lung cancer. Their study showed that artificial intelligence allows a a more precise diagnosis of small and medium-sized lesions.

Finkle *et al.* [25] found that numerical indices that allow quantitative calculations in PET/CT provide an approximation to risk calculation in patients with non-small cell lung cancer. They did their work by applying the staging rules of the eighth edition of the TNM system [26]. They state that the indices allow the health care team to incorporate concepts such as prognostic value, associated with total tumor volume and TNM-calculated stage, which can serve to improve the accuracy of predicting overall survival.

These findings were corroborated in a recent study conducted by Tosi's group [27] in patients with stage I non-small cell lung cancer. Their research confirms that SUV_{max} and TLG - total tumor glycolysis measurements correlate adequately with the recurrence-free rate in patients with lung adenocarcinoma who have undergone lobectomy.

7. Use of quantitative

Positron emission tomography studies began in the 1970s. With the use of PET/CT, it is possible to carry out a metabolic study of tumors and to reach numerical conclusions that allow quantitative evaluation of what is found in patients with neoplasms. Lammertsma states not to use semiquantitative indexes indiscriminately, but to base oneself on clinical judgment and careful and meticulous inspection of the images [28]. This effort is possible if the patient had been examined previously. In PET/CT studies, it is common practice to compare the latest results with the previous examinations to evaluate the efficacy of various treatments.

Hua et al. [29] consider that numerical parameters are extremely important when evaluating the possibility of mediastinal lymph node metastasis. In this work they mention that PET-CT with ^{18}F-FDG has a sensitivity of 81.3% and specificity of 79.4% for detecting mediastinal metastatic lymph nodes, with a SUV_{max} value of 2.5 as a cut-off point; however, the false positive rate is relatively high, which is up to

61.1 %.

Therefore, the authors evaluated several morphological and metabolic parameters in 206 mediastinal lymph nodes of 156 patients with non-small cell lung cancer, concluding that the combined parameters, such as SUV ratio (SUV_{max} node/SUV_{max} mediastinum), COV (coefficient of variation of heterogeneity) and D_{min} (maximum short diameter) showed better diagnostic performance for detecting metastatic mediastinal lymph nodes, with 87.38%, 81.55%, 84.47%, 82.57%, and 86.6% for sensitivity, specificity, accuracy, positive predictive value, and negative predictive value respectively. They conclude that their results have limitations because the sample size was small, but multicenter studies may be carried out in the future.

Lee *et al.* [30] used a double check-in time (early and late study) of PET/CT images and concluded that they have an adequate diagnostic system for the detection of metastases in mediastinal nodes in patients with non-small cell lung cancer with the same accuracy in the early and late study. They suggested that multicenter studies should be carried out with this methodology to firmly establish the usefulness of the late images.

8. Evaluation of the effect of selected treatment for non-small cell cancer and follow-up of patients

Eze *et al.* [31] have studied the status of the method, limitations, and possible future uses of hybrid imaging such as PET/CT to evaluate the treatment efficacy and toxicity of some new drugs, such as immunotherapy in patients with locally advanced, inoperable, and metastatic non-small cell lung cancer. They concluded that as new forms of immunotherapy are developed for locally advanced lung cancer, new patterns of response, disease progression and side effects of these drugs are being seen. They mentioned that adding PET/CT to existing imaging techniques can provide clinical support and more morphological information, allowing early detection of side effects and effective decision-making.

Gamal reported in his study which consisted of 63 patients that [32] PET/CT plays an important role in distinguishing post-treatment changes in patients with non-small cell lung cancer from tumor recurrence. He emphasizes the value of the study for calculating the patient's overall survival, and stated that multicenter studies with a larger number of cases are needed to draw conclusions regarding the predictive value of the study.

Zheng *et al.* [33] studied the application of radiomics in the PET/CT evaluation of 716 patients with non-small cell lung cancer, with pre- and post-surgery evaluation of mediastinal nodes. They conclude that a radiomics model applied to this technology and the analysis of the data is useful in the evaluation of mediastinal node staging in patients with non-small cell lung cancer. This evaluation method allows for a better treatment plan according to the preoperative prediction and to offer alternatives of less radical surgery or stereotactic body radiotherapy in selected cases. All this effort requires a very strict quality control of the equipment to be used.

Jahangiri et al. [34] determined that the inflammatory component can be seen following radiotherapy of patients with non-small cell lung cancer. The changes in PET/CT images before and after receiving radiotherapy were evaluated in the form of proton therapy in order to quantify the inflammatory response in patients with advanced stage lung cancer.

Being able to diagnose this inflammatory response suggests that PET/CT parameters could serve as biomarkers of radiation pneumonitis in these cases and guide subsequent therapeutic management.

Fledelius *et al.* [35] found that the outcome of adjuvant chemotherapy can be assessed in patients with non-small cell lung cancer prior to radiotherapy, suggesting that a quantitative method (in this case Positron Emission Tomography Response Criteria [PERCIST]) be used instead of visual assessments alone. Further studies are required to reach definitive conclusions. What is clear is the usefulness of PET/CT in the follow-up of these patients, before, during, and after selected treatment.

There are ongoing controlled clinical trials that have reported that pretreatment tumor volume can maybe predict the response to chemo- and radiotherapy. However, a recent study contradicts this claim. Guberina *et al.* [36] state that quantitative PET/CT values after induction chemotherapy are better predictors of survival than pretreatment findings.

Therefore, it can be affirmed that a decrease in SUV (numerical value of PET/CT) serves to predict survival in patients with stage III non-small cell lung cancer without being able to draw conclusions or extrapolate results to other stages or to the stage prior to chemotherapy, and these studies still require validation with larger series.

Horn and his team [37] studied the application of PET/CT in chemo-radiotherapy regimens, since it would be possible to find susceptible areas of treatment that have not responded to initial chemotherapy. They acknowledged that there are limitations and that the results of ongoing work in various parts of the world are still required. They emphasized that quantitative parameters should be simplified, which can be applicable to various brands of PET/CT equipment.

9. Recent advances based on the metabolic characteristics of the tumor

In recent years, immune therapy-based on immune checkpoint inhibitors targeting the programmed death-1 (PD-1) axis and programmed death ligand 1 (PD-L1) has been incorporated into the field of therapy. However, the evaluation of immunohistochemical biomarkers for targeted therapy, as well as the scoring of the proportion of PD-L1 in the tumor, have had serious limitations in terms of interobserver reproducibility, clones, and epitopes used for their evaluation, and automated biomarker processing systems. Zhou *et al* [38] have presented a model for predicting response to immunotherapy that takes into account the correlation between PD-L1 and PET/CT findings in patients with non-small cell lung cancer. They stated that FDG-PET/CT radiomic features are sufficient to predict the presence of tumor immune types, indicating that quantitative PET/CT could be used to guide candidates for immunotherapy. Similar conclusions were also drawn by a study by Valentinuzzi *et al.* [39], who suggest combining iRECIST parameters with PET/CT radiomic parameters in order to determine the response to immunotherapy.

Studies have affirmed that immunotherapy is an established treatment for malignant tumors, particularly in advanced cases, in which progression-free survival was improved [41]. Therefore, there is great room for research and therapeutic management to offer a better quality of life to patients with non-small cell lung cancer.

10. Cost-effectiveness studies

Much effort has been put into using available technology and reducing costs to make diagnosis prior to and after treatment for non-small cell lung cancer more affordable.

Han et al. [41] from China have designed 4 models for the management of mediastinal lymph node involvement in non-small cell lung cancer, regarding the use of diagnostic images: Model A consisted of using CT only, Model B used PET/CT only if the CT was negative, model C involved both methods, and model D, is PET/CT only. Using various economic indicators, they concluded that Model C was more cost-effective in the country where the study was performed, and that method was introduced to aid staging strategies, reduce surgical mortality, and extend survival expectancy.

Johnson's team [42] in Australia has published a study in which, by studying the timing of PET/CT in patients with non-small cell lung cancer, they determine that, against the "CT first" system, it may be decided to perform FDG-PET/CT first, prior to biopsy attempts, which may reduce the number of patients who will need more than one biopsy. However, they acknowledge that the clinical significance and a prospective evaluation of the overall cost-benefit of this type of patient management still needs to be further studied.

Several limitations were reviewed in the studies. For example, in terms of the waiting time to perform imaging studies, long waiting periods could be detrimental to the health of patients with non-small cell lung cancer because of its aggressive nature. On the other hand, in terms of diagnostic samples, little tissue is obtained in some cases, which greatly limits the diagnosis and follow-up in spite of all the imaging studies. There remains fertile ground for study in these topics, even more so in issues that have not been addressed, such as the prediction of the type of pathological markers associated with PET/CT iin advanced immunotherapy, which is very expensive but apparently effective in other latitudes.

11. Conclusion

In conclusion, PET/CT study is useful in the staging and follow-up of the proposed treatment for patients with non-small cell lung cancer. This malignant tumor is often diagnosed at the advanced stage. It is crucial to determine the lines of research and further study the treatments available in Peru and utilize the best of the technology available. Much progress has been made and numerical data are available to support a coordinated and systematic study. The lines of research can be oriented towards improving the conditions of the equipment in use, so that quantitative parameters can be calculated accurately, and personalized treatments can be offered, thus prognosis of each individual patient can be improved.

Another line of research proposed is prospective studies of patients with non-small cell lung cancer, having PET/CT images after each therapy they receive and disseminate articles that have an impact on the framework of prevention and early diagnosis, to ensure that this tumor is diagnosed at earlier stages, which will allow better management and survival; in other words, changing the history of the patient with non-small cell lung cancer in Peru.

Disclosure statement

The authors declare no conflict of interest.

References

[1] Fischer B, Lassen U, Mortensen J, et al., 2009, Preoperative Staging of Lung Cancer with Combined PET-CT. The New England Journal of Medicine, 361(1): 32–39.

[2] Farsad M, 2020, FDG PET/CT in the Staging of Lung Cancer. Current Radiopharmaceuticals, 13(3): 195–203.

[3] World Cancer Observatory, n.d., viewed July 19, 2022, https://gco.iarc.fr/today/data/factsheets/cancers/15-Lung-factsheet.pdf

[4] National Institute of Neoplastic Diseases, 2019, Health Manual: Cancer Prevention, https://portal.inen.sld.pe/wp-content/uploads/2019/10/MANUAL-PREVENCION-CANCER_final-16.01.19.pdf

[5] Lima N, Cancela M, Becerra D, et al., 2022, Spatial Assessment of Advanced-Stage Diagnosis and Lung Cancer Mortality in Brazil. Plos One, 17(3): e0265321. https://doi.org/10.1371/journal.pone.0265321

[6] Mu W, Jiang L, Zhang J, et al., 2020, Non-Invasive Decision Support for NSCLC Treatment Using PET/CT Radiomics. Nature Communications, 11: 5228. https://doi.org/10.1038/s41467-020-19116-x

[7] Maurer M, Kasmann L, Fleischmann D, et al., 2022, PET/CT-Based Adaptive Radiotherapy of Locally Advanced Non-Small Cell Lung Cancer in Multicenter yDEGRO ARO 2017-01 Cohort Study. Radiation Oncology, 17: 29. https://doi.org/10.1186/s13014-022-01997-5

[8] Han Y, Ma Y, Wu Z, et al., 2020, Histologic Subtype Classification of Non-Small Cell Lung Cancer Using PET/CT Images. European Journal of Nuclear Medicine and Molecular Imaging. 48: 350–360. https://doi.org/10.1007/s00259-020-04771-5

[9] Popat S, Navani N, Smit E, et al., 2021, Navigating Diagnostic and Treatment Decisionsin Non-Small Cell Lung Cancer: Expert Commentary onthe Multidisciplinary Team Approach. The Oncologist, 26(2): e306–e315. https://academic.oup.com/oncolo/article/26/2/e306/6445376

[10] Kaseda K, 2020, Recent and Current Advances in FDG-PET Imaging within the Field of Clinical Oncology in NSCLC: A Review of the Literature. Diagnostics, 10(8): 561. https://doi.org/10.3390/diagnostics10080561

[11] Chan J, Yu P, Lau R, Ng C, 2020, Hybrid Operating Room—Onestop for Diagnosis, Staging and Treatment of Early Stage NSCLC. J Thorac Dis, 12(2): 123–131.

[12] Machado T, Altmayer S, Watte G, et al., 2020, 18F-FDG PET/CT and Whole-Body MRI Diagnostic Performance in M Staging for Non–Small Cell Lung Cancer: A Systematic Review and Meta-Analysis. European Radiology, 30: 3641–3649.

[13] Rossi G, Russo A, Tagliamento M, et al., 2020, Precision Medicine for NSCLC in the Era of Immunotherapy: New Biomarkers to Select the Most Suitable Treatment or the Most Suitable Patient. Cancers, 12(5): 1125. https://doi.org/10.3390/cancers12051125

[14] Al-Ibraheem A, Hirmas N, Fanti S, et al., 2021, Impact of 18F-FDG PET/CT, CT andEBUS/ TBNA on Preoperative Mediastinal Nodal Staging of NSCLC. BMC Medical Imaging 21: 49. https://doi.org/10.1186/s12880-021-00580-w

[15] Osarogiagbon R, 2018, Staging of Lymph Nodes in Early Stage NSCLC: Therapeutic Implications. Journal of Thoracic Oncology, 13: 10S.

[16] Hochhegger B, Tronco G, Irion K, et al., PET/CT Imaging in Lung Cancer: Indications and Findings. J Bras Pneumol, 41(3): 264–274. https://doi.org/10.1590/S1806-37132015000004479

[17] Zhao L, He Z, Zhong X, et al., 2012, 18FDG-PET/CT for Detection of Mediastinal Nodal Metastasis in Non-Small Cell Lung Cancer: A Meta-Analysis. Surgical Oncology, 21: 230–236.

[18] Osman A, Korashi H, 2020, PET/CT Implication on Bronchogeniccarcinoma TNM Staging and Follow-up using RECIST/PERCIST Criteria: A Comparative Study with CT. Egyptian Journal of Radiology and Nuclear Medicine, 51: 16. https://doi.org/10.1186/s43055-020-0133-5

[19] Kandathil A, Kay F, Butt Y, et al., 2018, Role of FDG PET/CT in the Eighth Edition of TNM Staging of Non-Small Cell Lung Cancer. Radiographics, 38(7): 2134–2149. https://doi.org/10.1148/rg.2018180060

[20] De Cecco CN, Burchett P, van Assen M, et al., Rationale and Design of a Prospective Study on the First Integrated PET/Dual Energy CT system for Staging and Image-Based Radiation Therapy Planning of Lung Cancer. European Radiology Experimental, 2: 15. https://doi.org/10.1186/s41747-018-0047-4

[21] Lim C, Park S, Kim H, et al., 2022, Clinical Value of Surveillance 18F-fluorodeoxyglucose PET/CT for Detecting Unsuspected Recurrence or Second Primary Cancer in Non-Small Cell Lung Cancer after Curative Therapy. Cancers, 14(3): 632. https:// doi.org/10.3390/cancers14030632

[22] Zhu X, Liao C, Penney B, et al., 2017, Prognostic Value of Quantitative PET/CT in Patients with a Non-Small Cell Lung Cancer and Another Primary Cancer. Nuclear Medicine Communications, 38: 185–192.

[23] Dashevsky B, Zhang C, Yan L, et al., 2017, Whole Body Metabolic Tumor Volume is a Prognostic

Marker in Patients with Newly Diagnosed Stage 3B Non-Small Cell Lung Cancer, Confirmed with External Validation. European Journal of Hybrid Imaging, 1(1): 8.

[24] Borrelli P, Ly J, Kaboteh R, et al., 2021, AI-based Detection of Lung Lesions in [18F] FDG PET-CT from Lung Cancer Patients. EJNMMI Physics, 8: 32. https://doi.org/10.1186/s40658-021-00376-5

[25] Finkle J, Penney B, Pu Y, 2018, An Updated and Validated PET/CT Volumetric Prognostic Index for Non-Small Cell Lung Cancer. Lung Cancer Journal. https://doi.org/10.1016/j.lungcan.2018.07.019

[26] Lababede O, Meziane M, 2018, The Eighth Edition of TNM Staging of Lung Cancer: Reference Chart and Diagrams. The Oncologist, 23(7): 844–848.

[27] Tosi D, Pieropan S, Cattoni M, et al., 2021, Prognostic Value of 18F-FDGPET/CT Metabolic Parameters in Surgically Treated Stage I Lung Adenocarcinoma Patients. Clin Nuc Med, 46(8): 621–626.

[28] Lammertsma A, 2018, Forward to the Past: The Case for Quantitative PET Imaging. J Nucl Med, 58(7): 1019–1024. https://doi.org/10.2967/jnumed.116.188029

[29] Hua J, Li L, Liu L, et al., 2021, The Diagnostic Value of Metabolic, Morphological and Heterogeneous Parameters of 18F-FDG PET/CT in Mediastinal Lymph Node Metastasis of Non-Small Cell Lung Cancer. Nuclear Medicine Communications. 42(11): 1247–1253. https://doi.org/10.1097/MNM.0000000000001456

[30] Lee S, Kim S, 2022, Is Delayed Image of 18F-FDG PET/CT Necessary for Mediastinal Lymph Node Staging in Non–Small Cell Lung Cancer Patients? Clinical Nuclear Medicine, 47(5): 414–421. https://doi.org/10.1097/RLU.0000000000004110

[31] Eze C, Schmidt-Hegemann N, Sawicki L, et al., 2021, PET/CT Imaging for Evaluation of Multimodal Treatment Efficacy and Toxicity in Advanced NSCLC—Current State and Future Directions. European Journal of Nuclear Medicine and Molecular Imaging. 48: 3975–3989. https://doi.org/10.1007/s00259-021-05211-8

[32] Gamal G, 2021, The Usefulness of 18F-FDG PET/CT in Follow-up and Recurrence Detection for Patients with Lung Carcinoma and its Impact on the Survival Outcome. Egyptian Journal of Radiology and Nuclear Medicine, 52: 121. https://doi.org/10.1186/s43055-021-00504-2

[33] Zheng K, Wang X, Jiang C, et al., 2021, Pre-Operative Prediction of Mediastinal Node Metastasis Using Radiomics Model Based on 18F-FDG PET/CT of the Primary Tumor in Non-Small Cell Lung Cancer Patients. Frontiers in Medicine, 8: 673876. https://doi.org/10.3389/fmed.2021.673876

[34] Jahangiri P, Dreyfuss A, Duan F, et al., 2021, Implementation of FDG-PET/CT Imaging Methodology for Quantification of Inflammatory Response in Patients with Locally Advanced Non-Small Cell Lung Cancer: Results from the ACRIN 6668/RTOG0235 Trial. Am J Nucl Med Mol Imaging, 11(5): 415–427.

[35] Fledelius J, Khalil A, Hjorthaug K, et al., 2016, Inter-Observer Agreement Improves with PERCIST 1.0 as Opposed to Qualitative Evaluation in Non-Small Cell Lung Cancer Patients Evaluated with F-18-FDG PET/CT Early in the Course of Chemo-Radiotherapy. EJNMMI Research, 6: 71. https://doi.org/10.1186/s13550-016-0223-6

[36] Guberina M, Eberhardt W, Stuschke M, et al., 2019, Pretreatment Metabolic Tumor Volume in Stage III A/B Non-Small-Cell Lung Cancer Uncovers Differences in Effectiveness of Definitive Radio Chemotherapy Schedules: Analysis of the ESPATUE Randomized Phase 3 Trial. European Journal of Nuclear Medicine and Molecular Imaging. 46:1439–1447. https://doi.org/10.1007/s00259-019-4270-x

[37] Horn K, Thomas H, Vesselle H, et al., 2021, Reliability of Quantitative 18F-FDG PET/CT Imaging Biomarkers for Classifying Early Response to Chemoradiotherapy in Patients with Locally Advanced Non–Small Cell Lung Cancer. Clin Nucl Med, 46: 861–871. https://doi.org/10.1097/RLU.0000000000003774

[38] Zhou J, Zou S, Kuang D, et al., 2021, A Novel Approach using FDG PET/CT-Based Radiomics to Assess Tumor Immune Phenotypes in Patients with Non-Small Cell Lung Cancer. Front. Oncol, https://doi.org/10.3389/fonc.2021.769272

[39] Valentinuzzi D, Vrankar M, Boc N, et al., 2020, [18F] FDG PET Immunotherapy Radiomics Signature (iRADIOMICS) Predicts Response of Non-Small Cell Lung Cancer Patients Treated with Pembrolizumab. Radiol Oncol. 54(3): 285–294. https://doi.org/10.2478/raon-2020-0042

[40] Teixidó C, Vilariño N, Reyes R, et al., 2018, PD-L1 Expression Testing in Non-Small Cell Lung Cancer. Therapeutic Advances in Medical Oncology, 10: 1–17.

[41] Han Y, Xiao H, Zhou Z, et al., 2015, Cost-Effectiveness Analysis of Strategies Introducing Integrated 18F-FDG PET/CT into the Mediastinal Lymph Node Staging of Non-Small-Cell Lung Cancer. Nuclear Medicine Communications, 36: 234–241.

[42] Johnson A, Norman R, Piccolo F, et al., 2021, The Optimal Timing of FDG-PET/CT in Non-Small Cell Lung Cancer Diagnosis and Staging in an Australian Centre. BMC PulmMed, 21: 209. https://doi.org/10.1186/s12890-021-01564-w

Publisher's note

Bio-Byword Scientific Publishing remains neutral with regard to jurisdictional claims in published maps and institutional affiliations.

Oncology Treatment Discovery, 2023, Volume 1, Issue 1
http://ojs.bbwpublisher.com/index.php/OTD

Prevalence of End-of-Life Signs and Symptoms in Glioblastoma Patients: A Descriptive and Retrospective Study

Liliana Frazão Vasconcelos*, Mafalda Monteiro Ferreira, José Maria Bandeira Costa

Neurology/Hematology and Medical Oncology Department, Oncology Institute Francisco Gentil, Lisbon 1099-023, Portugal

***Corresponding author:** Liliana Frazão Vasconcelos, Vasconcelosliliana vasconcelos88@gmail.com

Copyright: © 2023 Author(s). This is an open-access article distributed under the terms of the Creative Commons Attribution License (CC BY 4.0), permitting distribution and reproduction in any medium, provided the original work is cited.

Abstract: *Introduction:* Glioblastoma is often associated with a poor prognosis. The end-of-life signs and symptoms of these people differ from the rest of the cancer population. *Objective:* To identify the main signs and symptoms present in the last seven days of life of patients with glioblastoma in a neurological oncology service. *Methods:* A descriptive and retrospective study was carried out. The sample included patients diagnosed with glioblastoma with medical and nursing records of the last seven days of life that were admitted to the Neurology service and admitted to the institution by the neuro-oncology consultation between 2019 and 2020. Data was collected from the medical records of the patients. *Results:* Medical records of 17 patients were selected for this study. The main signs and symptoms present in the last seven days of their lives were decreased level of consciousness (94%), rare and unexpected events (94%), respiratory dysfunction (88%), and loss of swallowing ability (76%). *Conclusion:* The objectives of this study were achieved. However, it is important to conduct studies in this population with more representative samples, since most literature is focused on the oncologic population in general.

Keywords: Glioblastoma; End-of-life signs and symptoms; Palliative care; Nursing care

Online publication: May 17, 2023

1. Problem statement

Primary central nervous system (CNS) tumors are associated with high morbidity and mortality rates. According to the World Health Organization (WHO), there was a worldwide incidence of 308,102 new cases and a mortality rate of 251,329 cases in 2020 [1]. In Portugal, the incidence of new cases was 1,105, with a mortality rate of 933 cases [1]. Primary CNS tumors are classified based on histopathological characteristics, with glioblastoma representing 17% of these tumors [2]. According to the WHO classifications, glioblastomas are classified as a grade IV tumor, from the group of diffuse astrocytic and oligodendroglia tumors. They are subdivided into wildtype isocitrate dehydrogenase (IDH) glioblastomas, which account for about 90% of cases, and mutant IDH-glioblastomas, which account for approximately the remaining 10% of cases [3]. Despite the development of techniques for early diagnosis and treatment, the diagnosis and palliative prognosis of glioblastoma continues to be poor [4–7]. For the treatment of glioblastoma, surgery is used (although total resection of the tumor is not possible because it is very vascularized and infiltrative), radiotherapy with adjuvant chemotherapy and maintenance chemotherapy [8,9]. With the available treatment methods, the average survival time for these patients is between 15 and 18 months [2].

In recent years, taking into account the prognosis of this cancer, studies have been conducted to focus on the end-of-life experience of glioblastoma patients, considering that the signs and symptoms of these patients differ from those of the general cancer population [10] and of patients with brain metastasis [11]. Glioblastoma patients often have a worsened general condition, increased health care needs and high levels of family burnout [9]. They may also experience high levels of distress related to cognitive, physical, and emotional symptoms, which will affect their quality of life and functional independence [6,12]. It should be noted that the onset of signs and symptoms may be progressive or rapid depending on the location of the tumor in the brain [13].

In a systematic literature review by Walbert & Khan [10] on symptoms of primary brain tumors at end-of-life encompassing articles between 1946 and 2013, the authors concluded that both the symptoms presented, and their frequency differed from other cancer patients at end-of-life. Decreased consciousness, altered communication, confusion, dysphagia, seizures, and headaches were the most prevalent symptoms. In a study on symptoms presented by 57 glioblastoma patients in the last 10 days of life [11], decreased consciousness, fever, dysphagia, seizures, and headaches were the most frequently emerging symptoms.

Chaichana *et al.* [14] analyzed 544 patients with glioblastoma who underwent surgical resection and scored above 80 on the Karnofsky Scale and found that 56% were no longer functionally independent 10 months after surgery. Removal of the tumor not only leads to functional decline, but also cognitive decline, and the treatments and therapies used will also cause some side effects. Therefore, it is important to discuss the therapeutic plan in a timely manner in order to reduce morbidity and restore or preserve neurological functions to allow patients to perform their daily activities [15].

The complexity of symptoms inherent to this cancer along with its poor prognosis makes the integration of a palliative care philosophy essential. There may be challenges to the integration of palliative care in neuro-oncology due to myths, lack of training of neuro-oncology palliative care professionals, distress, fears, and the patient's/informal caregiver's literacy [6,11].

In a preliminary search in the electronic databases CINAHL and MEDLINE of the platform EBSCOhost Integrated Search, a few articles on the topic was found, but Portuguese nursing publications in this area were not accessible. There is therefore a need to systematize the knowledge about the signs and symptoms present at the end of life in patients with glioblastoma admitted to the inpatient unit, in order to plan individualized and effective nursing care. Thus, the central research question was defined as follows: What are the main signs and symptoms present in the last seven days of life in patients with glioblastoma admitted to the Neurology Department?

The general objective of this study is to identify the main signs and symptoms present in the last seven days of life of patients with glioblastoma. The specific objectives are as follows: (i) To characterize a cohort of patients with glioblastoma in the last seven days of life in terms of gender and age; (ii) to estimate the prevalence of signs and symptoms present in the last seven days of life of patients with glioblastoma.

2. Material and methods

2.1. Type of study

This is a descriptive and retrospective study regarding the signs and symptoms in the last seven days of life of patients with glioblastoma who were admitted to the Neurology Service of a national oncology referral center through neuro-oncology consultation during the years 2019 and 2020.

2.2. Population and sample

The population includes all adult patients diagnosed with glioblastoma with medical and nursing records in the last seven days of life, admitted to the Neurology service of a national oncology referral center admitted through a neuro-oncology consultation in 2019 and 2020. The period of consultation of the files

is justified by the quality indicator in palliative care concerning physical aspects, which recommends the "recording of the absence or presence of symptoms in the last seven days of the patient's life, regardless of their state of consciousness" [16].

2.2.1. Inclusion criteria

The inclusion criteria were as follows: patients diagnosed with glioblastoma who were admitted to the Neurology service through neuro-oncology consultation during the years 2019 and 2020, who died during inpatient care and who were hospitalized for seven days or more.

2.2.2. Exclusion criteria

The exclusion criteria were as follows: patients diagnosed with glioblastoma whose admission did not fall within the time period previously defined and whose length of stay was less than seven days, even if they died in the Neurology service. Patients who were not admitted to the institution through neuro-oncology consultation were excluded.

2.3. Data collection and instruments used

Data collection was performed through a retrospective analysis of medical and nursing records of the selected patients. The compilation of files took place between April and October 2021 in the Neurology Department of a national oncology referral center.

The data collection tool used was based on the document "The Last Hours of Living" [17] a table was created, which consisted of the following items: (i) symptoms that appeared in the last seven days of life (classified as present or absent); (ii) the place of data collection (medical or nursing record); (iii) the frequency (days), in which they are present. In this data collection instrument, it is also specified that the type of CNS tumor must be glioblastoma; the gender and age of the patient, the duration of hospitalization, and whether the support of the Intra-hospital Palliative Care Support Team was requested were also recorded. A statistical analysis of the data was performed using Microsoft Excel.

2.4. Ethical considerations

The participants' information was kept confidential throughout the study and the study was approved by the Ethics Committee of Oncology Institute Francisco Gentil (Opinion number: UIC1440/2021).

3. Results and discussion

3.1. Results

17 people (13 men and 4 women) were included in this study, admitted for an average of 17.3 days and with an average age of 61.8 years old for men and 63 years old for women.

Using the data collection tool mentioned above, the signs and symptoms that emerged most frequently (94%) were decreased level of consciousness, rare and unexpected events and respiratory dysfunction. This was followed by loss of swallowing ability (76%). The prevalence of signs and symptoms that emerged from the data collection is presented in **Figure 1**.

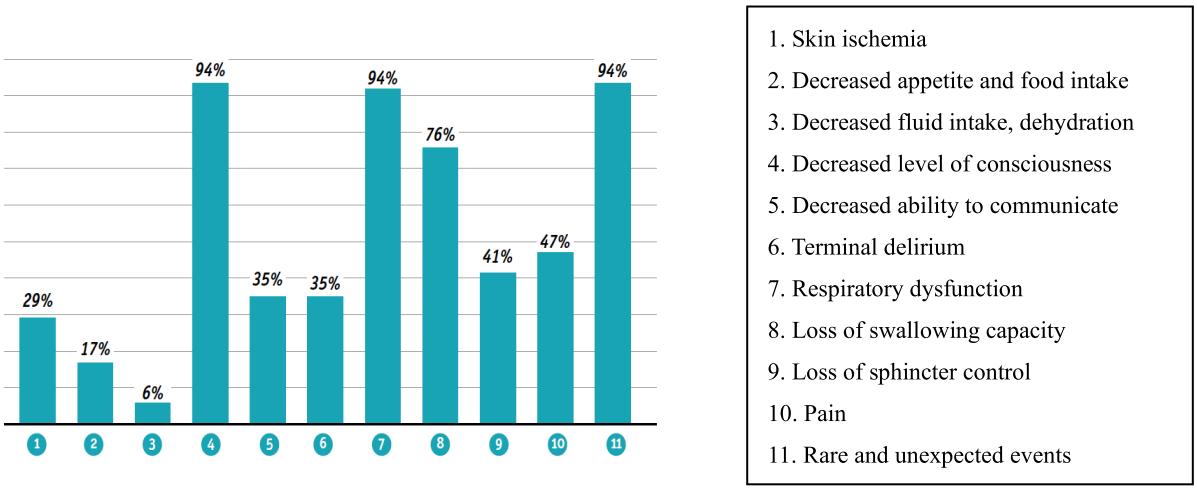

Figure 1. Prevalence of signs and symptoms in the last 7 days of life.

Rare and unexpected events in the files were described as fever, myoclonus, and convulsion, nausea and vomiting, insomnia, anxiety, candidiasis, and traumatic wound. **Figure 2** shows the frequency (no. of cases) with which they were recorded.

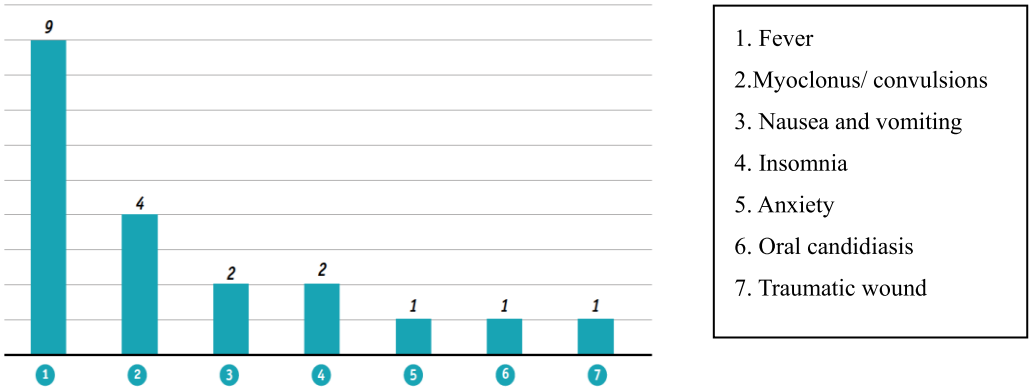

Figure 2. Frequency of the no. of rare and unexpected events (no. of cases)

The decreased level of consciousness was described as “prostration” in 14 people and “stupor” in 2 people. Regarding respiratory dysfunction, “wheezing” was recorded in 14 people and “polypnea” in 4 people. The loss of swallowing ability is reported as “no safe oral route” in 12 people and “dysphagia” in 1 person.

Of the 8 people who experienced pain, their pain were described as “grimacing pain” (4 people), “groaning” (2 people), “lower back pain” (1 person) and “headaches” (1 person).

In 76.4% of the sample the support of the Intra-Hospital Palliative Care Support Team was requested.

There were parameters that were not registered in the medical and nursing clinical records, namely “fatigue, weakness,” “cardiac dysfunction, renal dysfunction,” and “loss of ability to close the eyes.”

3.2. Discussion

The number of patients included in this study was small, which is in line with the frequency and representativeness of this diagnosis when compared to other oncologic diseases [1]. We also found that there was a higher prevalence of the disease among male patients, which coincides with what is described in the scientific evidence [1,2].

The most prevalent signs and symptoms in this study were decreased level of consciousness,

respiratory dysfunction, and the appearance of rare and unexpected events. It was found that it is unanimous in the literature that these patients present alterations in the state of consciousness afterwards, with periods of increased sleepiness, which affected their ability to communicate [10-12,18,19].

Many studies pointed out communication disorders as a prevalent symptom at the end of life of these patients, which makes it difficult to assess symptoms on a first-person basis [10,11,19]. In our studied, communication disorders were explicitly recorded in 6 people.

The respiratory dysfunction present in 16 patients in our study differed from the prevalence presented in several scientific studies. Although this symptom is not so significant in the studies, there was also appearance of dyspnea or accumulation of secretions in the airways at the end of life of these patients [10-12], which justifies the data obtained.

The category of rare and unexpected events emerged from the data collection tool used, which is more directed to the oncologic population in general. Thus, all the symptoms that appeared in the clinical files and that did not fit the signs and symptoms described in the instrument were included in the rare and unexpected events, namely fever (9 people) and myoclonus/convulsions (5 people). Myoclonus/convulsions are described in studies as very prevalent [10,13,18,19].

In our sample, we also found a high prevalence of swallowing alterations, namely the absence of a safe oral pathway, which is also in line with scientific evidence [10,11]. It should be noted that anorexia is one of the most frequent symptoms at the end of life of the oncologic population [20]. However, it is not confirmed since the change is in the state of consciousness and loss of appetite [10,12].

The prevalence of pain in our study is in agreement with other studies, which highlights the possibility of this symptom appearing less frequently in these patients when compared to the rest of the cancer population [12,22].

The prevalence of the aforementioned signs and symptoms makes it essential to reflect on the therapeutic routes of administration in order to promote symptomatic control [23].

There are a few limitations to this study. Firstly, the small sample size of this study does not allow us to generalize the results obtained. Besides, the data collection instrument is not validated for the Portuguese population. Lastly, the bibliographic references on the subject were mostly over five years old.

4. Conclusion

This study aimed to identify the signs and symptoms of patients diagnosed with glioblastoma in the last seven days of life. Through retrospective analysis of clinical files, it was concluded that the most prevalent signs and symptoms are decreased state of consciousness, respiratory dysfunction (dyspnea or accumulation of secretions in the airways), appearance of rare and unexpected events (fever and myoclonus/convulsions) and loss of swallowing ability. The results obtained are in agreement with the scientific evidence, although a higher prevalence of patients with respiratory dysfunction was identified.

The pharmacological approach to symptom management should be improved since the appearance of swallowing disorders is very frequent in this population, which makes the oral route unsafe.

The knowledge obtained in this article allows health care professionals to have a better understanding of the signs and symptoms of end-of-life in people diagnosed with glioblastoma, so that better care can be provided.

The importance of addressing end-of-life care planning with these patients in advance is emphasized since there is a decrease in the state of consciousness and changes in communication as the disease progresses. In this sense, early discussions with palliative care teams is important for the prevention and effective treatment of symptoms, psychosocial accompaniment, and improvement of quality of life.

Finally, it should be noted that the recording of signs, symptoms, planned and performed nursing interventions, as well as the evaluation of their effectiveness is essential to ensure the quality and

individuality of care, translating into health gains.

Disclosure statement

The author declares no conflict of interest.

References

[1] Portugal, n.d., viewed April 2021, https://gco.iarc.fr/today/data/factsheets/populations/620-portugal-fact-sheets.pdf

[2] Abrey L, Mason W, 2011, Fast Facts: Brain Tumors. Karger Publishers, Basel, 144

[3] Louis D, Perry A, Reifenberger G, et al., 2016, The 2016 World Health Organization Classification if Tumors of the Central Nervous System: A Summary. Acta Neuropathol. 131(6): 803–820.

[4] Bi W, Beroukjim R, 2014, Beating the Odds: Extreme Long-Term Survival with Glioblastoma. Neuro Oncol.,16(9): 1159–1160.

[5] Kuchinad K, Strowd R, Evans A, et al., 2017, End-of-Life Care for Glioblastoma Patients in a Large Academic Center. J Neuro Oncol., 134(1): 75–81.

[6] Tan AC, Ashley DM, López GY, et al., 2020, Management of Glioblastoma: State of the Art and Future Directions. CA Cancer J Clin., 70(4): 299–312.

[7] Le Rhun E, Preusser M, Roth P, et al., 2019, Molecular Targeted Therapy of Glioblastoma. Cancer Treat Rev., 80: 101896.

[8] Persaud-Sharma D, 2018, Cerebral Gliomas: Treatment, Prognosis and Palliative Alternatives. Prog Palliat Care, 26(1): 7–13.

[9] Oronsky B, Reid TR, Oronsky A, et al., 2021, A Review of Newly Diagnosed Glioblastoma. Front Oncol., 10: 574012.

[10] Walbert T, Khan M, 2014, End-of-life Symptoms and Care in Patients with Primary Malignant Brain Tumors: A Systematic Literature Review. J Neurooncol., 117(2): 217–224.

[11] Thier K, Calabek B, Tinchon A, et al., 2016, The Last 10 Days of Patients with Glioblastoma: Assessment of Clinical Signs and Symptoms as well as Treatment. Am J Hosp Palliat Care, 33(10): 1–4.

[12] Crooms R, Goldstein NE, Diamond EL, et al., 2020, Palliative Care in High-Grade Glioma: A Review. Brain Sci, 10(723): 1–26.

[13] Cahill J, Armstrong T, 2011, Caring for an Adult with a Malignant Primary Brain Tumor. Nursing, 41(6): 28–33.

[14] Chaichana K, Halthore A, Parker SL, et al., 2011, Factors Involved in Maintaining Prolonged Functional Independence Following Supratentorial Glioblastoma Resection. J Neurosurg, 114(3): 604–612.

[15] Bergo E, Lombardi G, Guglieri I, et al., 2019, Neurocognitive Functions and Health-Related Quality of Life in Glioblastoma Patients: A Concise Review of the Literature. Eur J Cancer Car, 28(1): e12410.

[16] Capelas M, 2014, Quality Indicators for Palliative Care Services in Portugal, Católica University Press, Lisbon, 286.

[17] Emanuel L, Ferris F, von Gunten C, et al., 2010, The Last Hours of Living: Practical Advice for Clinicians, Medscape Internal Medicine, viewed April 2021, http://www.medscape.org/viewarticle/716874.

[18] Sizoo E, Braam L, Postma TJ, et al., 2010, Symptoms and Problems in the End-of-Life Phase of High-Grade Glioma Patients. Neuro Oncol., 12(11): 1162–1166.

[19] Sizoo E, Pasman HRW, Dirven, et al., 2014, The End-of-Life Phase of High-Grade Gliomapatients: A Systematic Review. Support Care Cancer, 22(3): 847–857.

[20] Ross DD, Alexander CS, 2001, Management of Common Symptoms in Terminally Ill Patients: Part I. Fatigue, Anorexia, Cachexia, Nausea and Vomiting. Am Fam Physician, 64(5): 807–814.

[21] Ross DD, Alexander CS, 2001, Management of Common Symptoms in the Terminally Ill: Part II. Am Fam Physician, 64(6): 1019–1026.

[22] Walbert T, 2017, Palliative Care, End-of-Life Care, and Advance Care Planning in Neuro-Oncology. Continuum (MinneapMinn), 23(6): 1709–1726.

[23] Koekkoek J, Sizoo EM, Pasman HRW, 2014, Symptoms and Medication Management in the End-of-Life Phase of High-Grade Glioma Patients. JNeurooncol, 120(3): 589–595.

Publisher's note

Bio-Byword Scientific Publishing remains neutral with regard to jurisdictional claims in published maps and institutional affiliations.

Oncology Treatment Discovery, 2023, Volume 1, Issue 1
http://ojs.bbwpublisher.com/index.php/OTD

Clinical Value Analysis of Pemetrexed Combined with Cisplatin in the Treatment of Non-Small Cell Lung Cancer

Feifei Zhao*

Shengli Oilfield Central Hospital, Dongying 257000, Shandong Province, China

***Corresponding author:** Feifei Zhao, zhaofei534098@163.com

Copyright: © 2023 Author(s). This is an open-access article distributed under the terms of the Creative Commons Attribution License (CC BY 4.0), permitting distribution and reproduction in any medium, provided the original work is cited.

Abstract: *Objective:* To analyze the clinical value of pemetrexed combined with cisplatin in the treatment of non-small cell lung cancer (NSCLC). *Methods:* Sixty-nine patients in Shengli Oilfield Central Hospital were recruited between May 2021 and August 2022 and separated into the observation group (n = 35) and the control group (n = 34). Cisplatin combined with pemetrexed (the observation group) and cisplatin combined with gemcitabine (the control group) were used for treatment, respectively, and the therapeutic effects of the two groups were compared. *Results:* There was no significant difference in the disease control rate between the two groups ($P > 0.05$); the immune function indexes of the patients in the observation group were significantly higher than those in the control group after treatment ($P < 0.05$); there was no significant difference in the incidence of nausea and vomiting as well as hair loss ($P > 0.05$), but the incidence of blood toxicity in the observation group was significantly lower than that in the control group ($P < 0.05$). *Conclusion:* Pemetrexed plus cisplatin in NSCLC patients has an ideal effect, and it can improve the quality of life of patients and reduce adverse reactions, which has clinical promotion value.

Keywords: Pemetrexed; Cisplatin; Non-small cell lung cancer; Clinical value

Online publication: March 28, 2023

1. Introduction

Lung cancer is a very common type of cancer where a harmful malignant tumor grows in the lungs. Recently, 1.4 million people have been diagnosed every year, and the prevalence and mortality have been rising [1,2]. Among them, non-small cell lung cancer (NSCLC) accounts for about 80% of lung cancers. Many patients miss the best opportunity for treatment and often seek medical attention during the middle and late stages of lung cancer [3,4]. Therefore, the purpose of clinical treatment is to alleviate the patient's symptoms as much as possible and prolong the patient's survival period. Currently, platinum-based chemotherapy is the main treatment for NSCLC, but the efficacy is unsatisfactory, as it has only a 20%–40% effective rate [5]. This article analyzed the clinical effect and safety of 69 patients with NSCLC who received pemetrexed and cisplatin combined therapy, aiming to further explore the efficacy of this treatment plan.

2. Materials and methods

A retrospective study was carried out between May 2021 and August 2022 at the Shengli Oilfield Central Hospital, China. Inclusion criteria included patients being diagnosed with NSCLC, patients who did not receive relevant treatment or had received chemotherapy but within 2 treatment courses before participating

in this study, with expected survival time of over 0.5 years and KPS score of more than 60 points, as well as no other serious diseases such as coronary heart disease, renal failure, liver failure, etc. Exclusion criteria included the following: (1) lack of diagnosis and treatment data; (2) combined with other serious malignant tumors; (3) intolerant to the drug of study; (4) abnormal menstrual blood and electrocardiogram examination before treatment; and (5) lost contact during follow-up or left halfway through the study. Sixty-nine patients aged 48–79 who fulfilled the inclusion criteria were recruited, informed, and signed the consent form. They were then randomly divided into 2 groups: the observation group (male:female = 18:17 [51.43%:48.57%]; mean age = 63.54 ± 4.89 years old), and the control group (male:female = 18:16 [52.94%:47.06%]; mean age = 63.78 ± 4.02 years old).

Both groups of patients received cisplatin therapy with a dose of 75 mg/m^2 divided into 3 days via intravenous infusion, and the infusion time was over 2 hours. Appropriate diuretic treatment was given before and after treatment.

The control group was treated with cisplatin combined with gemcitabine, and the patients were intravenously infused with 100 mg/m^2 of gemcitabine and 100 mL of normal saline on the first and eighth day of the treatment, and the infusion lasted for 30 minutes.

The observation group was treated with a combination of pemetrexed and cisplatin; 500 mg/m^2 of pemetrexed was injected into 100 mL of normal saline and administered intravenously on the first day of treatment. Over a cycle of 21 days, 400 μg/d of pemetrexed oral folic acid was given from 1 week before chemotherapy to 3 weeks after the end of chemotherapy, while vitamin B12 was given one week before pemetrexed injection, once every 3 weeks. On the day of administration and the following day, 4 mg of oral dexamethasone were given twice a day, and an intramuscular injection of 1,000 μg vitamin B12 was administered, followed by cisplatin infusion starting 30 minutes after the end of pemetrexed infusion.

The effect judgment included short-term efficacy analysis, immune function indexes, as well as adverse reactions. The short-term efficacy analysis included complete response (CR), partial response (PR), stable disease (SD), progressive disease (PD), overall response rate (ORR; the sum of CR and PR), and disease control rate (DCR; the sum of CR, PR, and SD).

Statistical software SPSS 22.0 was used in this study to process data. The measurement data were represented by mean ± standard deviation (SD), and the *t*-test was used. Enumeration data were expressed in %, and the χ^2 test was used. The difference was statistically significant when $P < 0.05$.

3. Results

3.1. Comparison of the short-term efficacy between the two groups

As shown in **Table 1**, there was no significant difference in the disease control rate between the two groups ($P > 0.05$).

Table 1. Comparison of the short-term efficacy between the two groups

Group	Number of cases	CR	PR	SD	PD	RR	DCR
Observation group	35	5 (14.29%)	21 (45.71%)	6 (17.14%)	3 (8.57%)	26 (74.29%)	32 (91.43%)
Control group	34	4 (11.76%)	21 (47.06%)	5 (14.71%)	4 (11.76%)	25 (73.53%)	30 (88.24%)
χ^2		0.128	0.000	0.076	0.193	0.005	0.193
P		0.721	1.000	0.782	0.660	0.943	0.660

3.2. Comparison of changes in humoral immune function indexes between the two groups

As shown in **Table 2**, the cellular immune function indexes of the two groups of patients before

chemotherapy were similar ($P > 0.05$), whereas, after chemotherapy, the cellular immune function indexes of the observation group were significantly higher than those of the control group ($P = 0.016$ for IgA; $P = 0.000$ for IgG, IgM, and IgE).

Table 2. Comparison of changes in humoral immune function indexes

Group	Number of cases	IgG (g/L)		IgA (mg/L)		IgM (mg/L)		IgE (mg/L)	
		Before chemo	After chemo	Before chemo	After chemo	Before chemo	After chemo	Before chemo	After chemo
Observation group	35	6.59 ± 2.47	6.45 ± 0.21	1.67 ± 0.42	1.61 ± 0.57	1.52 ± 0.35	1.50 ± 0.03	1.69 ± 0.35	1.61 ± 0.47
Control group	34	6.23 ± 2.35	5.12 ± 0.35	1.68 ± 0.68	1.31 ± 0.43	1.43 ± 0.31	1.01 ± 0.03	1.73 ± 0.48	1.13 ± 0.35
t		0.620	19.205	0.074	2.463	1.130	67.830	0.396	4.800
P		0.537	0.000	0.941	0.016	0.263	0.000	0.693	0.000

3.3. Comparison of the adverse reactions' incidence between the two groups

As shown in **Table 3**, during the treatment, there was no significant difference in the incidence of nausea, vomiting, and hair loss between the two groups ($P > 0.05$), but the incidence of blood toxicity in the observation group was significantly lower than that in the control group ($P = 0.009$).

Table 3. Comparison of the adverse reactions' incidence between the two groups

Group	Number of cases	Hair loss	Nausea and vomiting	Blood toxicity
Observation group	35	1 (2.86%)	2 (5.88%)	0 (0.00%)
Control group	34	2 (5.88%)	1 (2.94%)	6 (17.65%)
χ^2		0.380	0.319	6.765
P		0.538	0.572	0.009

4. Discussion

Lung cancer is one of the most common malignancies, and NSCLC is the dominant type. Patients who are diagnosed with NSCLC are not suitable for surgical treatment [6,7]. Currently, chemotherapy is the main treatment method. It is necessary to be attentive to its effectiveness and side effects when using specific drugs during the treatment. From the 1960s to the 1970s, platinum-based drugs were widely used in the treatment of lung cancer. However, due to the poor treatment effect and obvious side effects, platinum-containing regimens have been gradually updated and iterated in the treatment of lung cancer. Nowadays, the first-line treatment is a platinum-based two-dose combination regimen, and the application of new chemotherapeutic drugs, such as pemetrexed, docetaxel, and gemcitabine, has further improved the effectiveness of lung cancer treatment [8,9]. In recent years, the treatment of advanced NSCLC has advanced rapidly. Among them, the application of drugs such as vinorelbine, paclitaxel, irinotecan, and pemetrexed has significantly improved the chemotherapy effect on lung cancer and reduced its side effects. Recent large-scale randomized controlled studies have shown that the combination of new chemotherapeutic drugs and platinum-based drugs as third-generation chemotherapy regimens have a better therapeutic effect than second-generation platinum-containing regimens and can achieve a cure rate of 30%–40%. Pemetrexed, as a first-line or second-line treatment drug, has a significant effect on the 1-year survival rate of patients with NSCLC [10,11].

Pemetrexed is a novel antineoplastic drug that disrupts folate-dependent cell replication processes. It inhibits the activity of all the folate-dependent enzymes, thymidylate synthase (TS), dihydrofolate reductase (DHFR), and glycinamide ribonucleotide formyltransferase (GARFT), thereby reducing the biosynthesis of purine and thymidine nucleotides and inhibiting the DNA and RNA production of tumor cells [12]. Pemetrexed has also been shown to have antitumor properties in a variety of tumors, including colorectal, breast, lung, pancreatic, and gastric cancers.

Pemetrexed performs well in the treatment of malignant mesothelioma where non-surgical treatment is feasible. It can significantly relieve symptoms when used alone or in combination with platinum-based drugs and has become one of the standard drugs for advanced malignant mesothelioma. Several clinical studies have shown that when pemetrexed is used in combination with cisplatin, the effective rate and median survival time of newly diagnosed NSCLC are better than those of pemetrexed alone. Among them, two phase I clinical studies have shown that the RR and DCR of combination therapy were 74.29% and 91.43%, respectively, and the median survival time reached 10.9 months and 8.9 months, respectively [13]; while the effective rate of pemetrexed alone was only 16% and 23%, respectively. A total of 571 NSCLC patients participated in a large-scale randomized clinical study to compare the second-line treatment effects of single-agent pemetrexed and paclitaxel. The results of the study showed that there was no significant difference between the two drugs in terms of effective rate (9.1% vs 8.8%), median survival (8.3 months vs 7.9 months), and 1-year survival rate (both 29.7%) [14]. Side effects including neutropenia, fever, and hair loss were noted, where the pemetrexed group had significantly reduced adverse reactions, as compared to the paclitaxel group. Based on this study, the US Food and Drug Administration (FDA) approved pemetrexed as a first-line drug for the treatment of locally advanced and metastatic NSCLC in August 2004. The study achieved a PR rate of 21.05% and a clinical utilization rate of 57.89% with the pemetrexed combined with a cisplatin regimen, similar to the results reported in the existing literature. The use of pemetrexed can cause various rare and severe side effects, such as leukopenia, rash, anemia, abnormal liver function, thrombocytopenia, and many more [15]. To reduce the occurrence of bone marrow toxicity, patients need to consume folic acid and vitamins. In addition, taking oral dexamethasone can prevent a rash from developing. All patients who took dexamethasone orally supplemented with folic acid and vitamins were found with no rash and white blood cell decline. Symptomatic treatment is effective for patients with leukopenia and non-hematological toxicity.

Gemcitabine belongs to difluoronucleoside antineoplastic drugs, which inhibit the proliferation of cancer cells and disrupt cell replication. The study showed that the RR and DCR of the observation group were 74.29% and 91.43%, respectively, as compared to the control group, despite no statistically significant difference between the two groups ($P > 0.05$). Compared with pemetrexed, gemcitabine resulted in poorer immune indexes, and the incidence of alopecia, nausea, and vomiting among other adverse reactions had no significant difference between the use of the two drugs ($P > 0.05$). This further verified the research point of view, suggesting that the combination of pemetrexed and cisplatin is indeed effective, which is the same as Qiu Pei's study [16], confirming that there was no statistically significant difference in adverse reactions between the pemetrexed group and the gemcitabine group.

5. Conclusion

In summary, chemotherapy is the main treatment option for patients diagnosed with NSCLC, who realize the futility of surgery during the advanced stages of the disease, but the effect of chemotherapy alone is limited. Therefore, the comprehensive use of pemetrexed combined with cisplatin as first-line treatment can not only enhance the therapeutic effect and promote the relief of patient indicators and symptoms but also reduce side effects and improve treatment comfort and compliance. In addition, comprehensive treatment is expected to stabilize the disease and improve the survival rate of patients.

Disclosure statement

The author declares no conflict of interest.

References

[1] Li Y, Liu J, Zhou Z, et al., 2018, Comparative Study of Pemetrexed and Gemcitabine Combined with Cisplatin in the First-Line Treatment of Advanced Non-Small Cell Lung Cancer. J Bengbu Med Coll, 43(6): 719–722.

[2] Xue Y, Jia J, Wu Y, et al., 2018, Clinical Effects of Gemcitabine and Pemetrexed Combined with Cisplatin in the Treatment of Non-Small Cell Lung Cancer. PLA J Med, 30(12): 11–14.

[3] Chen C, Wang Y, Zhou Y, 2018, Clinical Feasibility of Pemetrexed Combined with Cisplatin in the Treatment of Non-Small Cell Lung Cancer. J Pract Cancer, 33(6): 941–943.

[4] Zhu Y, Wang R, Li A, et al., The Effect of Pemetrexed Combined with Cisplatin on the Expression of CEA and Other Markers in Patients with Advanced Non-Small Cell Lung Cancer. J Diff Dis, 20(10): 982–986.

[5] Huang H, Chen T, 2018, The Effect of Pemetrexed Combined with Cisplatin on Serum Tumor Markers in Patients with Advanced Non-Squamous Non-Small Cell Lung Cancer. Drug Eval Res, 41(12): 2289–2293.

[6] Meng J, Wang M, Li J, et al., 2018, Clinical Study of Crizotinib versus Pemetrexed Disodium Combined with Cisplatin in the First-Line Treatment of ALK-Positive Advanced Non-Small Cell Lung Cancer. Int Oncol J, 45(1): 63–64.

[7] Wang Y, Quan L, 2020, Effects of Pemetrexed and Cisplatin Combined with Gefitinib on T Cell Subsets and Cytokines in Patients with Lung Cancer. Southeast Def Med, 22(1): 43–47.

[8] Luo X, Ma Y, Sun Z, et al., 2019, Clinical Research on Xiaoai Ping Tablets Combined with PC Regimen in the Treatment of Advanced Non-Small Cell Lung Cancer. Mod Drugs Clinics, 34(2): 424–428.

[9] Li Z, Yang Y, Zhang L, 2018, Application of Gemcitabine or Pemetrexed Intravenous Chemotherapy Combined with Cisplatin Pleural Infusion in Non-Small Cell Lung Cancer with Malignant Pleural Effusion. Cancer Prog, 16(3): 342–344 + 374.

[10] Jia L, Zhu Y, Fu Y, et al., 2018, Efficacy and Safety Evaluation of Compound Matrine Injection on Pemetrexed Combined with Carboplatin Regimen in the Treatment of Non-Small Cell Lung Cancer. Chin Mod Appl Pharm, 35(10): 1533–1537.

[11] Wang W, Dong L, Li H, et al., 2020, Clinical Observation of Anlotinib Combined with Chemotherapy as Second-Line Treatment of Advanced Non-Small Cell Lung Cancer with Acquired Resistance to Tyrosine Kinase Inhibitors. Chin J Cancer Prevent Treat, 27(20): 1669–1673.

[12] Gao N, Wang C, 2022, Clinical Efficacy Study of Thymosin Combined with Cisplatin and Pemetrexed Disodium in the Treatment of Advanced Non-Small Cell Lung Cancer. Shaanxi Med J, 51(11): 1424–1427.

[13] Li Z, Yang D, He W, et al., 2022, Application Effect of *Brucea javanica* Oil Emulsion Injection Combined with Pemetrexed + Cisplatin Chemotherapy in Non-Small Cell Lung Cancer. Cancer Prog, 20(7): 672–675.

[14] Chang Y, Zhang L, Wang H, et al., 2022, Observation on the Curative Effect of Gefitinib Combined

with Pemetrexed and Cisplatin in the Treatment of Advanced Non-Small Cell Lung Cancer. Chin Cancer Clinic Rehab, 29(2): 129–133.

[15] Zhang Y, Mo Q, He X, et al., 2018, Clinical Efficacy of Pemetrexed Combined with Cisplatin in the Treatment of Non-Small Cell Lung Cancer and Its Impact on the Quality of Life of Patients. Cancer Prog, 16(13): 1601–1603.

[16] Qiu P, Zhang Q, Chen L, et al., 2020, Efficacy of Pemetrexed Combined with Cisplatin in the Treatment of Advanced Non-Small Cell Lung Cancer and Its Impact on Patients' Toxic and Side Effects and 1-Year Survival Rate. Hebei Med, 26(3): 506–510.

Publisher's note

Bio-Byword Scientific Publishing remains neutral with regard to jurisdictional claims in published maps and institutional affiliations.

Oncology Treatment Discovery, 2023, Volume 1, Issue 1
http://ojs.bbwpublisher.com/index.php/OTD

Efficacy Analysis of Laparoscopic Myomectomy and Open Myomectomy in the Treatment of Uterine Fibroids

Yaqin Yang†, Liping Zhao*

The Third Hospital of Inner Mongolia Baotou Iron and Steel Group, Baotou 014010, Inner Mongolia Autonomous Region, China

***Corresponding author:** Liping Zhao, zlpingovh@126.com

†***First author:** Yaqin Yang, lzg8yyq@126.com

Copyright: © 2023 Author(s). This is an open-access article distributed under the terms of the Creative Commons Attribution License (CC BY 4.0), permitting distribution and reproduction in any medium, provided the original work is cited.

Abstract: *Objective:* To compare and analyze the effects of myomectomy by laparotomy and laparoscopy for uterine fibroids. *Methods:* 60 patients with uterine fibroids treated in the past 3 years (January 2020 to December 2022) were randomly divided into two groups according to the surgical plans, with 30 cases in each group. Patients in the control group underwent laparotomy, whereas those in the observation group underwent laparoscopic surgery. The effects were compared and analyzed. *Results:* Compared with the control group, the observation group had shorter surgery, time to first passage of flatus, and hospital stay; less intraoperative blood loss; lower complication rate; and higher postoperative quality-of-life score ($P < 0.05$). Although there was no significant difference between the two groups in terms of substance P (SP), interleukin 6 (IL-6), and prostaglandin E2 (PGE2) before surgery ($P > 0.05$), there was an increase in each index after surgery, but the increase in the observation group was less, as compared to the control group; the observation group had significantly lower levels of each index ($P < 0.05$). *Conclusion:* There are two common surgical approaches for myomectomy, laparotomy and laparoscopy. In comparison, the laparoscopic approach, a minimally invasive procedure, can optimize surgery-related indicators, reduce surgical trauma response, and reduce complications. It benefits patients by delivering favorable surgical outcomes and improving postoperative quality of life.

Keywords: Myomectomy; Laparotomy; Laparoscopic surgery; Complications; Trauma response

Online publication: March 28, 2023

1. Introduction

Most patients with clinically diagnosed uterine fibroids have no obvious symptoms. Only a small number of patients may present with vaginal bleeding, pain, or a palpable mass over the abdomen [1,2]. Uterine fibroids are benign tumors of the reproductive system that are common in clinical practice. The pathogenesis of the disease is not fully understood, but it has been speculated that the disease is related to high estrogen levels. Although uterine fibroids are benign lesions, their health hazards cannot be underestimated when enlarge. Active treatment is the key to preventing cancer. The clinical treatment of this disease is mainly surgery, and with today's technology, complete resection of uterine fibroids is feasible. The majority of traditional uterine fibroid removal procedures involve open surgery, which inevitably causes significant trauma and increases the risks for complications. Therefore, after the procedure, most patients will take a long time to recover, and the prognosis may be poor due to complications [3,4].

Laparoscopy is a minimally invasive technique, and its value has attracted much clinical attention. In the ever-advancing medical field, this technique has been applied in various surgeries. Practice has proven that laparoscopic surgery is less invasive, and patients tend to recover faster after surgery [5,6]. Hence, we conducted a study on patients with uterine fibroids with the aim of exploring the difference between laparoscopic surgery and laparotomy in the treatment of uterine fibroids.

2. Materials and methods

2.1. Baseline data

Sixty patients with uterine fibroids treated in the past 3 years (January 2020 to December 2022) were randomly divided into two groups according to the surgical plans, with 30 cases in each group. Patients in the control group underwent laparotomy, whereas patients in the observation group underwent laparoscopic surgery. The mean age of the patients in the two groups was 42.16 ± 2.75 (observation group) and 42.35 ± 2.86 (control group), respectively; the tumor diameters were 7.09 ± 0.56 cm (observation group) and 7.07 ± 0.49 cm (control group), respectively; and the disease duration was 8.99 ± 1.25 months (observation group) and 8.76 ± 1.19 months (control group), respectively. There were no differences between the two groups of patients in terms of baseline data ($P > 0.05$).

Inclusion criteria: (1) uterine fibroids confirmed by magnetic resonance imaging (MRI) or other imaging methods, which were consistent with postoperative pathological results; (2) complete diagnosis and treatment data; (3) patients and their families were informed and provided informed consent.

Exclusion criteria: (1) co-existence of malignant tumor; (2) mental disorder or language dysfunction; (3) contraindications to myomectomy; (4) dropped out of the study or poor compliance.

2.2. Surgical approach

2.2.1. Abdominal/Open myomectomy

Surgery was arranged within 1 week after the end of menstruation. Sterilized drapes were used, and the surgery was carried out with general anesthesia and the patient in supine position. An incision of about 8 cm in length was made 2 transverse fingers above the pubic symphysis; the abdomen was opened layer by layer. The abdominal cavity was opened to expose the uterus, and the location, size, shape, and other information of the fibroids were verified. After injecting 10 U of oxytocin, the fibroid tissue was removed by blunt dissection, and the abdominal cavity and pelvic cavity were washed. The residual cavity was sutured, bleeding was stopped, and the incision was closed. Antibiotic prophylaxis was initiated.

2.2.2. Laparoscopic myomectomy

The procedure was performed with general anesthesia and the patient kept in lithotomy position. Sterilized drapes were used. An incision of about 1 cm was made below the navel, and carbon dioxide (CO_2) was used to create a CO_2 pneumoperitoneum with a pressure of 15 mmHg. The pneumoperitoneum needle handle was taken out, and a laparoscope was used to observe the conditions in the pelvic cavity. After verifying the specific information of the fibroid tissue, the operating instrument was inserted through the hole. Vasopressin was applied locally, the capsule was cut with the help of an ultrasonic knife, and the fibroid tissue was grasped. After pulling the fibroid tissue with forceps, blunt separation and electrocoagulation were performed to stop the bleeding. The residual cavity was sutured with absorbable sutures. After the incision was closed, prophylaxis antibiotic was initiated.

2.3. Evaluation indicators

(1) Surgery-related indicators: operation time, intraoperative blood loss, time to first passage of flatus, and length of hospital stay.

(2) Incidence of complications: intestinal obstruction, emphysema, incision bleeding, and surgical site infection.
(3) Trauma response before and after surgery: substance P (SP), interleukin 6 (IL-6), and prostaglandin E_2 (PGE_2).
(4) Quality of life: SF-36 was used to evaluate quality of life; a higher score indicates better quality of life.

2.4. Statistical analysis

Data were processed using SPSS 20.0. Measurement data were represented by mean ± standard deviation, and *t*-test was used. Enumeration data were expressed in percentage (%), and χ^2 test was used. $P < 0.05$ indicates a statistically significant difference.

3. Results

3.1. Surgery-related indicators

Compared with the control group, the observation group had shorter surgery, intraoperative blood loss, time to first passage of flatus, and hospital stay ($P < 0.05$). See **Table 1** for details.

Table 1. Comparison of surgery-related indicators between the two groups

Group	Number of cases	Operation time (min)	Intraoperative blood loss (mL)	Time to first passage of flatus (h)	Length of hospital stay (d)
Observation group	30	49.28 ± 8.56	60.58 ± 11.25	18.02 ± 3.25	5.54 ± 0.98
Control group	30	65.78 ± 8.49	91.36 ± 11.75	26.98 ± 4.31	8.02 ± 1.04
t		7.496	10.364	9.092	9.506
P		0.000	0.000	0.000	0.000

Data are given as mean ± standard deviation.

3.2. Incidence of complications

The incidence of complications in the observation group was lower than that in the control group ($P < 0.05$). See **Table 2** for details.

Table 2. Comparing the incidence of complications between the two groups

Group	Number of cases	Intestinal obstruction	Emphysema	Incision bleeding	Surgical site infection	Incidence rate
Observation group	30	1 (3.33)	1 (3.33)	0 (0.00)	0 (0.00)	2 (6.67)
Control group	30	2 (6.67)	0 (0.00)	3 (10.00)	3 (10.00)	8 (26.67)
x^2		0.351	1.017	3.158	3.158	4.320
P		0.554	0.313	0.076	0.076	0.038

Data are given as n (%).

3.3. Trauma response before and after surgery

There was no significant difference in SP, IL-6, and PGE_2 between the two groups before surgery ($P > 0.05$). However, after surgery, each index increased, but the increase in the observation group was lesser than that in the control group; the levels of each index in the observation group were lower than those in the control group ($P < 0.05$). See **Table 3** for details.

Table 3. Comparison of trauma response between the two groups before and after surgery

Group	Number of cases	SP (μg/mL)		IL-6 (pg/mL)		PGE_2 (μg/mL)	
		Before surgery	After surgery	Before surgery	After surgery	Before surgery	After surgery
Observation group	30	3.99 ± 0.58	4.42 ± 0.36	5.42 ± 0.36	6.20 ± 0.71	102.36 ± 10.25	117.25 ± 11.54
Control group	30	3.98 ± 0.62	6.75 ± 0.41	5.43 ± 0.29	7.98 ± 0.85	102.45 ± 10.16	147.69 ± 11.39
t		0.065	23.390	0.119	8.803	0.034	10.283
P		0.949	0.000	0.906	0.000	0.973	0.000

Data are given as mean ± standard deviation.

3.4. Quality of life

The postoperative quality of life scores of the observation group were higher, as compared to the control group ($P < 0.05$). See **Table 4** for details.

Table 4. Comparison of quality-of-life scores between the two groups

Group	Number of cases	Quality-of-life score (points)			
		Social function	Mental health	Emotional function	Physiological function
Observation group	30	90.34 ± 4.15	92.33 ± 3.62	94.87 ± 12.18	96.15 ± 10.88
Control group	30	80.24 ± 6.45	86.35 ± 2.35	80.54 ± 11.04	82.14 ± 8.64
t		5.100	7.589	4.775	5.523
P		0.000	0.000	0.000	0.000
Group	**Number of cases**	**Quality-of-life score (points)**			
		Physical pain	**Physiological function**	**Vitality**	**General health**
Observation group	30	89.88 ± 5.41	92.32 ± 2.43	90.78 ± 3.74	91.48 ± 3.29
Control group	30	78.25 ± 5.37	87.52 ± 2.01	81.25 ± 4.36	83.66 ± 3.01
t		8.357	8.377	6.425	9.605
P		0.000	0.000	0.000	0.000

Data are given as mean ± standard deviation.

4. Discussion

In the past, open surgery was mainly used for patients with uterine fibroids. This surgical approach is also the earliest surgical plan in clinical practice, aiming at patients with tumor enlargement, large number of tumors, or tumors in special locations. This approach allows the removal of lesions to be more thorough and has a more significant effect. However, it has been found, through clinical practice, that open surgery causes considerable trauma and there are many postoperative complications that hinder the prognosis. In modern medicine, minimally invasive techniques have been popularized in the surgical field, and patients have higher requirements for surgical comfort and safety. Minimally invasive procedures have been generally recognized to have more advantage over conventional surgery and are more in line with the treatment needs of patients [7-10]. In particular, since many patients with uterine fibroids have fertility needs, they prefer minimally invasive surgery over conventional open surgery to reduce damage to the uterus and strive for faster recovery [11,12]. At present, the advantage of laparoscopic surgery has been widely

recognized. The advantage of laparoscopic myomectomy includes less trauma, smaller incision, faster recovery, less risk of infection, smaller postoperative scar, and better aesthetics; the field of view can be expanded for surgical exploration during surgery, and the relationship between the tumor tissue and adjacent tissues can be better distinguished under the visualization system, thus preventing unnecessary damage to adjacent tissues when the tumor tissue is removed; in addition, organs are less disturbed by the operations during surgery, resulting in not only less bleeding, but also unlikely postoperative pelvic adhesions [13-16].

In this study, the two approaches of myomectomy were compared, and the results showed that the observation group had shorter surgery, time to first passage of flatus, hospital stay, and intraoperative blood loss, as compared to the control group ($P < 0.05$). From the perspective of surgery-related indicators, the use of laparoscopic technology can further optimize indicators, such as intraoperative blood loss and speed of surgery; moreover, patients may recover faster after the procedure. Compared with the control group, the observation group had significantly lower incidence of complications ($P < 0.05$). With the assistance of laparoscopic technology, only a small operation hole is needed to complete the procedure, the environment in the abdomen and pelvis is less affected, the risk of infection is lower, and a wider field of view can be achieved, which is helpful to preventing unnecessary tissue injuries; in that way, the overall rate of complication is lower. Our study also found that although there were no significant differences between the two groups in terms of SP, IL-6, and PGE_2 before surgery ($P > 0.05$), both groups showed an increase in each index after surgery, but the increase was lower in the observation group, as compared to the control group and the levels of each index in the former group were lower than those in the control group ($P > 0.05$). Trauma response refers to the systemic reaction involving humoral, endocrine, nervous, and other systems when the body is damaged or dysfunctional. Since laparoscopic surgery is less invasive, the trauma response is less. Compared with the control group, the observation group had significantly higher postoperative quality-of-life scores ($P < 0.05$). Quality of life is an important indicator for prognosis; thus, the results confirmed that the prognosis of patients who undergo laparoscopic surgery would be more satisfactory.

In conclusion, myomectomy can be achieved by both laparotomy and laparoscopy, although the latter, as a minimally invasive procedure, can optimize surgical-related indicators, reduce the risk of complications, and lead to less traumatic response and better prognosis. Its value in surgery is high; thus, it is worth popularizing in clinical practice.

Disclosure statement

The authors declare no conflict of interest.

References

[1] Mu H, 2022, Comparison of Clinical Effects Between Laparoscopic Myomectomy and Traditional Open Myomectomy in the Treatment of Patients with Uterine Fibroids. Medical Equipment, 35(8): 88–90.

[2] Li Q, 2021, Comparison of Clinical Effects of Laparoscopic Myomectomy and Open Myomectomy in the Treatment of Uterine Fibroids. Chinese Medicine Guide, 19(17): 79–80.

[3] Li D, Chen C, Wang Y, 2021, Comparison of Clinical Effects Between Laparoscopic Myomectomy and Laparoscopic Myomectomy in the Treatment of Uterine Fibroids. Frontiers of Medicine, 11(6): 57–58.

[4] Qu J, Huang W, Lei X, 2020, Comparison of Clinical Effects of Laparoscopic In Situ Rotary Excision

and Laparotomy in the Treatment of Giant Uterine Fibroids. Frontiers of Medicine, 10(34): 134–135.

[5] Lu Y, 2021, Comparison of the Clinical Effect of Laparoscopic Myomectomy and Traditional Open Myomectomy in the Treatment of Giant Uterine Fibroids. Clinical Research, 29(2): 97–98.

[6] Huang J, 2021, Comparison of Clinical Effects of Laparoscopic Myomectomy and Laparotomy in the Treatment of Uterine Fibroids. World Compound Medicine, 7(2): 115–117.

[7] Guan X, Hua C, Wang S, et al., 2020, Comparison of Curative Effect Between Laparoscopic Myomectomy and Traditional Open Myomectomy in the Treatment of Giant Uterine Fibroids. Journal of Xinxiang Medical College, 37(3): 243–245 + 250.

[8] Zou Q, 2020, Analysis of Clinical Effect and Prognosis Quality of Minimally Invasive Laparoscopic Myomectomy for Patients with Uterine Fibroids. Chinese Medicine Innovation, 17(11): 126–129.

[9] Wang X, Xu L, Sun M, et al., 2021, Effects of Laparotomy and Laparoscopic Myomectomy on Myoma Recurrence, Oxidative Stress and Serological Trauma Indexes in Patients. Chinese Journal of Endoscopy, 27(4): 26–30.

[10] Shen Y, Shen B, 2021, Clinical Efficacy of Laparoscopic Uterine Artery Occlusion Combined with Myomectomy in the Treatment of Uterine Fibroids. Laboratory Medicine and Clinic, 18(19): 2830–2833.

[11] Xu Y, Zhang F, Meng H, et al., 2022, Observation on the Curative Effect of Laparoscopic Myomectomy and Traditional Laparotomy in the Treatment of Uterine Fibroids. Chinese Cancer Clinic and Rehabilitation, 29(5): 537–540.

[12] Tang Y, Wang X, Zhou X, 2021, Clinical Curative Effect of Laparoscopic Myomectomy and Its Influence on Hormone Indexes and Inflammatory Factor Levels of Patients. Journal of Bengbu Medical College, 46(1): 58–61.

[13] Liang L, Sun L, Yang B, et al., 2022, Efficacy of Laparoscopic Myomectomy in the Treatment of Uterine Fibroids and Its Impact on Postoperative Pregnancy. Chinese Maternal and Child Health, 37(1): 165–167.

[14] Tang K, Ma H, Liu P, 2022, Comparison of Efficacy and Safety of Transumbilical Single-Port Laparoscopy and Traditional Open Myomectomy. Anhui Medicine, 43(9): 1038–1041.

[15] Wang R, Wu W, Xu F, et al., 2020, Effects of Laparoscopic Myomectomy and Laparotomy on Endocrine Status, Immune Function and Prognosis of Patients with Uterine Fibroids. Advances in Modern Biomedicine, 20(16): 3160–3163.

[16] Cao X, Du L, Wang Q, et al., 2022, The Effect of Laparoscopic Myomectomy and Transabdominal Myomectomy in the Treatment of Uterine Fibroids. Jilin Medicine, 43(7): 1954–1956.

Publisher's note

Bio-Byword Scientific Publishing remains neutral with regard to jurisdictional claims in published maps and institutional affiliations.

Author Guidelines

Before your submission, please check that your manuscript has been prepared in accordance to the step-by-step instructions for submitting a manuscript to our online submission system. We recommend that you keep this page open for your reference as you move through the submission process.

If there are any differences in author guidelines between the print and online version, it is recommended that authors refer to the online version for use.

Manuscript Format

Oncology Treatment Discovery accepts manuscript that is in MS Word or LaTeX format. All manuscripts must be written in clear, comprehensible English. Both American and British English are acceptable. Usage of non-English words should be kept to a minimum and all must be italicized (except for e.g. and i.e.) If you have concerns about the level of English in your submission, please ensure that it is proofread before submission by a native English speaker or a scientific editing service.

Cover letter

All submissions for *Oncology Treatment Discovery* should include a cover letter as a separate file. A cover letter should contain a brief explanation of what was previously known, the conceptual advancement with the findings and its significance to broad readership. The cover letter is confidential and will be read only by the editors. It will not be seen by reviewers.

Title

The title should capture the conceptual significance for a broad audience. The title should not be more than 50 words and should be able to give readers an overall view of the paper's significance. Titles should avoid using uncommon jargons, abbreviations and punctuation.

List of Authors

The names of authors must be spelled out rather than set in initials with their affiliations footnoted. Authors should be listed according to the extent of their contribution, with the major contributor listed first. All corresponding authors (maximum 2) should be identified with an asterisk. Affiliations should contain the following core information: department, institution, city, state, postal code, and country. For contact, email address of only one corresponding author is expected within the manuscript. Please note that all authors must see and approve the final version of the manuscript before submitting.

Abstract

Articles must include an abstract containing a maximum of 200 words. The purpose of abstract is to provide sufficient information for a reader to choose either to proceed to the full text of the article. After the abstract, please give 3-8 key words; please avoid using the same words as those already used in the title.

Section Headings

Please number all section headings, subheadings and sub-subheadings. Use boldface to identify major headings (e.g. **1**, **2**, **3**, etc.) and subheadings (e.g. **1.1**, **1.2**, **2.1**, **2.2** etc.) For the sub-subheadings, please distinguish it further using non-boldface numbers in parenthesis (e.g. (1), (2), (3), etc.)

Introduction

Introduction should provide a background that gives a broad readership an overall outlook of the field and the research performed. It tackles a problem and states its important regarding with the significance of the study. Introduction can conclude with a brief statement of the aim of the work and a comment about whether that aim was achieved.

Materials and Methods

This section provides the general experimental design and methodologies used. The aim is to provide enough detail to for other investigators to fully replicate your results. It is also required to facilitate better understanding of the results obtained. Protocols and procedures for new methods must be included in detail to reproduce the experiments.

Ethics

Ethics information, including IACUC permit numbers and/or IRB name, if applicable. This information should be included in a subheading labelled "Ethics Statement" in the "Methods" section of your manuscript file, in as much detail as possible.

Results

This section can be divided into subheadings. This section focuses on the results of the experiments performed.

Discussion

This section should provide the significance of the results and identify the impact of the research in a broader context. It should not be redundant or similar to the content of the results section.

Conclusion

Please use the conclusion section for interpretation only, and not to summarize information already presented in the text or abstract.

Conflict of Interest

All authors are required to declare all activities that have the potential to be deemed as a source of competing interest in relations to their submitted manuscript. Examples of such activities could include personal or work-related relationships, events, etc. Authors who have nothing to declare are encouraged to add "No conflict of interest was reported by all authors" in this section.

Funding

Authors should declare all financial and non-financial support that have the potential to be deemed as a source of competing interest in relations to their submitted manuscript in this section. Financial supports are generally in the form of grants, royalties, consulting fees and more. Examples of non-financial support could include the following: externally-supplied equipments/biological sources, writing assistance, administrative support, contributions from non-authors etc.

Appendix

This section is optional and is for all materials (e.g. advanced technical details) that has been excluded from the main text but remain essential to readers in understanding the manuscripts. This section is

not for supplementary figures. Authors are advised to refer to the section on 'Supplementary figures' for such submissions.

Text

The text of the manuscript should be in Microsoft Word or Latex. The length of the manuscript cannot be more than 50000 characters (inclusive of spaces) or approximately 7000 words.

Nomenclature for genes and proteins

This journal aims to reach researchers all over the globe. Hence, for both reviewers' and readers' ease in comprehension, authors are highly encouraged to use the appropriate gene and protein nomenclature. Authors may prefer to utilize resources such as http://www.ncbi.nlm.nih.gov/gene

Figures

Authors should include all figures into the manuscript and submit it as 1 file in the OJS system. Reference to the "Instructions for Typesetting manuscript" is strongly encouraged. Figures include photographs, scanned images, graphs, charts and schematic diagrams. Figures submitted should avoid unnecessary decorative effects (e.g. 3D graphs) as well as be minimally processed (e.g. changes in brightness and contrast applied uniformly for the entire figure). It should also be set against a white background. Please remember to label all figures (e.g. axis etc.) and add in captions (below the figure) as required. These captions should be numbered (e.g. **Figure 1**, **Figure 2**, etc.) in boldface. All figures must have a brief title (also known as caption) that describes the entire figure without citing specific panels, followed by a legend defined as description of each panel. Please identify each panel with uppercase letters in parenthesis (e.g. A, B, C, etc.)

The preferred file formats for any separately submitted figure(s) are TIFF or JPEG. All figures should be legible in print form and of optimal resolution. Optimal resolutions preferred are 300 dots per inch for RBG coloured, 600 dots per inch for greyscale and 1200 dots per inch for line art. Although there are no file size limitation imposed, authors are highly encouraged to compress their figures to an ideal size without unduly affecting legibility and resolution of figures. This will also speed up the process of uploading in the submission system if necessary.

The Editor-in-Chief and Publisher reserve the right to request from author(s) the high-resolution files and unprocessed data and metadata files should the need arise at any point after manuscript submission for reasons such as production, evaluation or other purposes. The file name should allow for ease in identifying the associated manuscript submitted.

Tables, lists and equations

Tables, lists and equations must be submitted together with the manuscript. Likewise, lists and equations should be properly aligned and its meaning clear to readers. Tables created using Microsoft Word table function are preferred. Place each table in your manuscript file right after the paragraph in which it is first cited. Do not submit your tables in separate files. The tables should include a concise but sufficiently explanatory title at the top. Vertical lines should not be used to separate columns. Leave some extra space between the columns instead. All tables should be based on three horizontal lines to separate the caption, header and body. A few additional horizontal lines MAY be included as needed (example below). Any explanations essential to the understanding of the table should be given in footnotes at the bottom of the table. SI units should be used.

Supplementary information

This section is optional and contains all materials and figures that have been excluded from the entire manuscript. This information are relevant to the manuscript but remains non-essential to readers' understanding of the manuscript's main content. All supplementary information should be submitted as a separate file in Step 4 during submission. Please ensure the names of such files contain 'suppl. info'.

In-text citations

Reference citations in the text should be numbered consecutively in superscript square brackets. Some examples:

1. Negotiation research spans many disciplines [3, 4].
2. This result was later contradicted by Becker and Seligman [5].
3. This effect has been widely studied [1–3, 7].

Personal communications and unpublished works can only be used in the main text of the submission and are not to be placed in the Reference section. Authors are advised to limit such usage to the minimum. They should also be easily identifiable by stating the authors and year of such unpublished works or personal communications and the word 'Unpublished' in parenthesis.

E.g. (Smith J, 2000, Unpublished)

References

This section is compulsory and should be placed at the end of all manuscripts. Do not use footnotes or endnotes as a substitute for a reference list. The list of references should only include works that are cited in the text and that have been published or accepted for publication. Personal communications and unpublished works should be excluded from this section.

For references in reference list, all authors must be stated. Authors referenced are listed with their surname followed by their initials. All references should be numbered (e.g. 1. 2. 3. etc.) and sequenced according to the order it appears as an in-text citation. References should follow the following pattern: Author(s) followed by year of publication, title of publication, full journal name in italics, volume number, issue number in parenthesis, page range and lastly the DOI (if applicable). If the referred article has more than three authors, list only the first three authors and abbreviate the remaining authors to italicized 'et al.' (meaning: "and others").

Journal

Journal article (print) with one to three authors

[1] Yao Y., Xia B. Application of Phase Frequency Feature Group Delay Algorithm in Database Differential Access. Computer Simulation, 2014, 31(12): 238-241.

Journal article (print) with more than three authors

[2] Gamelin F.X., Baquet G., Berthoin S., et al. Effect of high intensity intermittent training on heart rate variability in prepubescent children. European Journal of Applied Physiology, 2009, 105: 731–738.

Journal article (online) with one to three authors

[3] Jackson D., Firtko A., Edenborough M. Personal resilience as a strategy for surviving and thriving in the face of workplace adversity: a literature review. Journal of Advanced Nursing, 2009, 60(1): 1–9,

Journal article (online) with more than three authors

[4] Hargreave M., Jensen A., Nielsen T.S.S., et al. Maternal use of fertility drugs and risk of cancer in children—A nationwide population-based cohort study in Denmark. International Journal of Cancer, 2015, 136(8): 1931–1939.

Book

Book with one to three authors

[5] Schneider Z., Whitehead D., Elliott D. Nursing and midwifery research: methods and appraisal for evidence-based practice. 3rd edn. 2009, Elsevier Australia, Marrickville, NSW.

Book with more than three authors

[6] Davis M., Charles L., Curry M.J., et al. Challenging spatial norms. 2013, Routledge, London.

Chapter or Article in Book

[7] Knowles M.S. Independent study. In Using learning contracts. 1986, Jossey-Bass, San Francisco, 89–96.

Others

Proceedings of meetings and symposiums, conference papers

[8] Chang S.S., Liaw L. and Ruppenhofer J. (eds). Proceedings of the twenty-fifth annual meeting of the Berkeley Linguistics Society, February 12–15, 1999: general session and parasession on loan word phenomena. 2000, Berkeley Linguistics Society, Berkeley.

Conference proceedings (from electronic database)

[9] Bukowski R.M. Prognostic factors for survival in metastatic renal cell carcinoma: update 2008. Innovations and challenges in renal cancer: proceedings of the third Cambridge conference. Cancer, 2009, 115 (10): 2273, viewed 19 May 2009, Academic OneFile database.

Online Document with author names

[10] Este J., Warren C., Connor L., et al. Life in the clickstream: the future of journalism, Media Entertainment and Arts Alliance, 2008. viewed 27 May 2009, http://www.alliance.org.au/documents/foj_report_final.pdf

Online Document without author name

[11] Developing an argument n.d., viewed March 30 2009, http://web.princeton.edu/sites/writing

/Writing_Center/WCWritingResources.htm

Thesis/Dissertation

[12] Gale L. The relationship between leadership and employee empowerment for successful total quality management. 2000, University of Western Sydney.

Standard

[13] Standards Australia Online. Glass in buildings: selection and installation. AS 1288–2006. 2006, SAI Global database.

Government Report

[14] National Commission of Audit. Report to the Commonwealth Government, Australian Government Publishing Service, 1996, Canberra.

Government report (online)

[15] Department of Health and Ageing. Ageing and aged care in Australia, 2008, viewed 10 November 2008, http://www.health.gov.au/internet/main/publishing.nsf/Content/ageing

No author

[16] Guide to agricultural meteorological practices. 2nd edn, Secretariat of the World Meteorological Organization, 2010, Geneva.

Note: When referencing an entry from a dictionary or an encyclopedia with no author there is no requirement to include the source in the reference list. In these cases, only cite the title and year of the source in-text. For an authored dictionary/encyclopedia, treat the source as an authored book.

Submission Preparation Checklist

As part of the submission process, authors are required to check off their submission's compliance with all of the following items, and submissions may be returned to authors that do not adhere to these guidelines.

1. The submission has not been previously published, nor is it before another journal for consideration (or an explanation has been provided in Comments to the Editor).

2. The submission file is in OpenOffice, Microsoft Word, RTF, or WordPerfect document file format.

3. Where available, URLs for the references have been provided.

4. The text is single-spaced; uses a 12-point font; employs italics, rather than underlining (except with URL addresses); and all illustrations, figures, and tables are placed within the text at the appropriate points, rather than at the end.

5. The text adheres to the stylistic and bibliographic requirements outlined in the Author Guidelines, which is found in About the Journal.

6. If submitting to a peer-reviewed section of the journal, the instructions in Ensuring a Blind Review have been followed.

Integrated Services Platform of International Scientific Cooperation

Innoscience Research (Malaysia), which is global market oriented, was founded in 2016.Innoscience Research focuses on services based on scientific research. By cooperating with universities and scientific institutes all over the world, it performs medical researches to benefit human beings and promotes the interdisciplinary and international exchanges among researchers.

Innoscience Research covers biology, chemistry, physics and many other disciplines. It mainly focuses on the improvement of human health. It aims to promote the cooperation, exploration and exchange among researchers from different countries. By establishing platforms, Innoscience integrates the demands from different fields to realize the combination of clinical research and basic research and to accelerate and deepen the international scientific cooperation.

Cooperation Mode

Clinical Workers

In-service Doctors

Foreign Researchers

Hospital

University

Scientific institutions

BIQ-BYWORD
SCIENTIFIC PUBLISHING PTY LTD

OUR JOURNALS

The *Journal of Architectural Research and Development* is an international peer-reviewed and open access journal which is devoted to establish a bridge between theory and practice in the fields of architectural and design research, urban planning and built environment research.

Topics covered but not limited to:

- Architectural design
- Architectural technology, including new technologies and energy saving technologies
- Architectural practice
- Urban planning
- Impacts of architecture on environment

Journal of Clinical and Nursing Research (JCNR) is an international, peer reviewed and open access journal that seeks to promote the development and exchange of knowledge which is directly relevant to all clinical and nursing research and practice. Articles which explore the meaning, prevention, treatment, outcome and impact of a high standard clinical and nursing practice and discipline are encouraged to be submitted as original article, review, case report, short communication and letters.

Topics covered by not limited to:

- Development of clinical and nursing research, evaluation, evidence-based practice and scientific enquiry
- Patients and family experiences of health care
- Clinical and nursing research to enhance patient safety and reduce harm to patients
- Ethics
- Clinical and Nursing history
- Medicine





Journal of Electronic Research and Application is an international, peer-reviewed and open access journal which publishes original articles, reviews, short communications, case studies and letters in the field of electronic research and application.

Topics covered but not limited to:

- Automation
- Circuit Analysis and Application
- Electric and Electronic Measurement Systems
- Electrical Engineering
- Electronic Materials
- Electronics and Communications Engineering
- Power Systems and Power Electronics
- Signal Processing
- Telecommunications Engineering
- Wireless and Mobile Communication