Urology Research

Editors-in-Chief

Arnold P. P. Achermann

University of Campinas, Brazil

Yunshan Zhang

Affiliated Hospital of Guangdong Medical University, China

BIO-BYWORD SCIENTIFIC PUBLISHING PTY LTD
(619 649 400)
Level 10
50 Clarence Street
SYDNEY NSW 2000
Copyright © 2023. Bio-Byword Scientific Publishing Pty Ltd.

Urology Research

Focus and Scope

Urology Research publishes peer-reviewed research articles across basic, translational, and clinical Urology medicine. The Journal covers all aspects of Urology medicine (full listing below) with an emphasis on studies that challenge the status quo of treatments and practices in Urology care or facilitate the translation of scientific advances into the clinic as new therapies or diagnostic tools.

About Publisher

Bio-Byword Scientific Publishing is a fast-growing, peer-reviewed and open access journal publisher, which is located in Sydney, Australia. As a dependable and credible corporation, it promotes and serves a broad range of subject areas for the benefit of humanity. By informing and educating a global community of scholars, practitioners, researchers and students, it endeavors to be the world's leading independent academic and professional publisher. To realize it, it keeps creative and innovative to meet the range of the authors' needs and publish the best of their work.

By cooperating with University of Sydney, University of New South Wales and other world-famous universities, Bio-Byword Scientific Publishing has established a huge publishing system based on hundreds of academic programs, and with a variety of journals in the subjects of medicine, construction, education and electronics.

Publication Headquarter

BIO-BYWORD SCIENTIFIC PUBLISHING PTY LTD
Level 10
50 Clarence Street
Sydney NSW 2000
Website: www.bbwpublisher.com
Email: info@bbwpublisher.com

2023, Volume 1, Issue 3

Table of Contents

1 **A Case Report of Bilateral Postoperative Inguinal Hernia Leading to Obstructive Azoospermia**
Guangjian Zhu

7 **Analysis of the Efficacy of Flexible Ureteroscopy and Rigid Ureteroscopy with Holmium Laser Lithotripsy in the Treatment of Upper Ureteral Stones in the Elderly**
Bing Zhou

12 **Analysis of the Effectiveness and Detection Rate of Urine Occult Blood Test in the Diagnosis of Urinary System Diseases**
Xiumei Zhu, Ying Dong, Lei Zhang

17 **Evaluation of the Effect of Transurethral Resection of Bladder Tumors in the Treatment of Bladder Cancer and its Impact on CA19-9 and CA125 Levels**
Peigeng Wang

23 **A Case Report of Metastatic Melanoma to the Bladder**
Ana María Ortiz-Zableh, Juan Manuel Sandoval-Ojeda, Natalia Patiño-Covelli, Isabel Cristina Bolívar-Aguilera, Alfredo Ortiz-Azuero

Urology Research, 2023, Volume 1, Issue 3
https://ojs.bbwpublisher.com/index.php/UR

A Case Report of Bilateral Postoperative Inguinal Hernia Leading to Obstructive Azoospermia

Guangjian Zhu*

People's Hospital of Yingde City Guangdong Province, Yingde 513000, Guangdong Province, China

***Corresponding author:** Guangjian Zhu, champion-dream@foxmail.com

Copyright: © 2023 Author(s). This is an open-access article distributed under the terms of the Creative Commons Attribution License (CC BY 4.0), permitting distribution and reproduction in any medium, provided the original work is cited.

Abstract: The study focused on a case involving a patient with bilateral inguinal hernia and obstructive azoospermia, who was admitted to People's Hospital of Yide City Guangdong Province on November 24, 2022. A comprehensive analysis of the patient's condition was conducted, including the determination of the surgical plan and exploration and analysis of key points related to surgical treatment and perioperative nursing intervention. The patient underwent a combined microscopic and laparoscopic exploration of both vas deferens and epididymis, with left epididymal anastomosis and right vas deferens recanalization. High-quality nursing intervention was implemented during the perioperative period. After treatment, the patient's examination results returned to normal, and his overall condition showed significant improvement, leading to a smooth discharge.

Keywords: Inguinal hernia; Azoospermia; Obstruction; Case analysis

Online publication: December 30, 2023

1. Introduction

Obstructive azoospermia primarily results from the blockage of sperm transport caused by obstruction of the vas deferens. Patients typically exhibit low or absent sperm secretion and abnormal changes in sperm volume. The primary causes of obstructive azoospermia encompass inflammation of the reproductive system, congenital bilateral vas deferens atresia or obstruction, epididymal duct agenesis, separation of the epididymis from the testis, vas deferens compression, inadvertent vas deferens injury during inguinal surgery, or perineal trauma. Notably, medical vas deferens injury stemming from inguinal hernia surgery stands out as the primary causative factor for this condition [1,2].

Clinical practice predominantly employs surgical treatments, especially inguinal hernia surgery, for obstructive azoospermia. To ensure the efficacy of surgical interventions, it is crucial to judiciously select the surgical approach and implement appropriate nursing interventions during the perioperative period [3]. This study focuses on a patient admitted to the People's Hospital of Yide City Guangdong Province, diagnosed with bilateral postoperative inguinal hernia leading to obstructive azoospermia. A detailed analysis of his medical records was conducted, and treatment and nursing programs were explored to provide valuable insights for

guiding clinical practice.

2. Case information

Patient Mr. Jiang, male, age 27 years old, was admitted to the hospital on November 24, 2022, due to his spouse's infertility, four months into their marriage. His semen analysis revealed a lack of sperm for the past two weeks.

Medical history: The patient reported a regular sex life since his marriage four months ago, with no issues such as erectile dysfunction, contraception use, ejaculation difficulties, premature ejaculation, or retrograde ejaculation. He denied experiencing urinary symptoms, scrotal cramps, or any abnormalities. Despite regular attempts, his spouse had not conceived. During an outpatient clinic review on November 23, 2022, an ultrasound examination revealed bilateral epididymis fine reticulation duct dilatation, indicating a possible vas deferens obstruction. Further assessment through transrectal prostate ultrasound showed bilateral enlarged seminal vesicles with glandular duct enlargement, leading to the diagnosis of obstructive azoospermia.

Past medical history: Mr. Jiang had no history of chronic diseases, infectious diseases, allergies to food or medications, trauma, or blood transfusion.

Personal history: There were no prevalent infectious diseases in Mr. Jiang's living area. He had no contact with infectious disease patients, toxic substances, or radioactive substances. Mr. Jiang reported no adverse habits.

Marital and family history: The patient is married, and the couple is childless. His spouse has no history of pregnancy, and there is no family history of similar diseases, hemophilia, thalassemia, mental illness, malignant tumors, or other genetic diseases.

Physical examination: The results of physical examination showed that the temperature (T) was 36.8°C, pulse (P) was 62 beats/min, respiratory rate (R) was 20 breaths/min, and blood pressure (BP) was 135/91 mm Hg. The patient presented with normal physical development, moderate nutrition, a smooth gait, natural expression, consciousness, and cooperative behavior during examination. The skin and mucous membrane tissues showed no signs of yellowish or pale discoloration, rashes, subcutaneous hemorrhages, or wounds. There was no enlargement of superficial lymph node tissues throughout the body. Head examination revealed no deformities, eyelid edema, eyebrow loss, bulbar conjunctival congestion, or edema. The eyes displayed normal movement, corneal transparency, equal-sized and round pupils, a sensitive light reflex, and a normal auricle. The nasal morphology was normal, lips were rosy, oral mucosa showed no ulceration or hemorrhage, and there was no enlargement of tonsils or pharyngeal congestion. The neck was soft and nonresistant, with a negative hepatic jugular venous reflux. The trachea was centrally positioned, and the thyroid appeared normal. Thoracic and abdominal examinations showed a symmetrical thorax without deformities, smooth and regular respiration, symmetrical respiratory motility bilaterally, clear sounds on percussion in both lungs and no wet or dry rales or pathologic murmurs in the valvular region. The abdomen was flat and soft, with no rebound pain or tenderness, a negative Murphy's sign, normal bowel sounds, and no mobile turbid sounds. Spinal limbs and neurological examinations indicated normal spinal limbs, no swelling in the lower limbs, presence of pharyngeal reflex, mandibular reflex, corneal reflex, normal muscle strength, normal muscle tone, normal sensory function, presence of muscle reflexes, knee reflexes, and periosteal reflexes. Additionally, there were no signs of meningeal irritation, and Babinski's sign was negative.

Specialized examination: During the specialized examination, the patient did not report any bulging in the region of both kidneys. The skin temperature was within normal range, and there was no evidence of pressure pain at the bilateral cribriform point and crib-waist point. No percussion pain was detected in both kidneys, and

there was no pressure pain in the bilateral ureters. A turbid sound in the bladder was observed under the pubic symphysis. The length of the surgical scar in the bilateral inguinal region was approximately 6 cm, without any nodules or secretion at the urethral orifices. Palpation of the testes bilaterally revealed no abnormalities, while firm nodules were palpated in the caudal part of the epididymis. The scrotal segment of vas deferens bilaterally could be palpated, with no observable beaded changes or varicose vein masses in the scrotum bilaterally. Additionally, the Valsalva maneuver was negative.

Auxiliary examination: On November 10, 2022, the semen analysis indicated a volume of 5 mL, a liquefaction time of 10 min, and a sperm density of 0. Subsequent examinations on November 15, 2022, conducted at other medical institutions revealed normal levels of sex hormones, a semen volume of 8 mL, and a liquefaction time of 30 min. However, the sperm density remained at 0. Results from tests for *Mycoplasma urealyticum* and chlamydia were negative. During a recheck at the outpatient clinic on November 23, 2022, a color ultrasound examination of the scrotum, testes, and spermatic vein was performed. The left testis measured approximately 45 mm × 17 mm, and the right testis measured about 43 mm × 18 mm, both exhibiting normal morphology, clear peritoneum, a smooth surface, and homogeneous hypoechoic testicular parenchyma. Color Doppler flow imaging (CDFI) revealed a stellate blood flow signal in the testis. Fine reticular ducts were observed to be dilated in both testes, and CDFI did not detect any abnormal blood flow signals. No isolated fluid dark areas were seen in the sheath lumen of the testes bilaterally, and the spermatic cords were not widened. Additionally, there were no varicose veins in the spermatic cords. The ultrasonographic diagnosis suggested bilateral dilatation of the fine reticular ducts of the testes, and obstruction of the vas deferens was considered.

Clinical diagnosis: The patient's initial diagnosis was obstructive azoospermia, with additional diagnoses of left epididymal obstruction and right vas deferens hypoplasia. The final diagnosis confirmed obstructive azoospermia, left epididymal obstruction, and right vas deferens hypoplasia.

3. Case analysis

Preoperative discussion and analysis comments:

(1) Preoperative preparation: The preoperative preparation was meticulously completed, and the patient exhibited no contraindications to the surgery.

(2) Indications for surgery. The patient's spouse experienced infertility after marriage, with two semen analyses revealing azoospermia. Hormone test results indicated normal testicular spermatogenesis, and ultrasound demonstrated bilateral vas deferens obstruction.

(3) Surgical program: The proposed surgical intervention involved bilateral vas deferens and epididymis exploration under a microscope combined with laparoscopy. The plan included left vas deferens epididymal anastomosis and right vas deferens recanalization.

(4) Proposed anesthesia plan: The anesthesia plan suggested static-aspiration compound general anesthesia.

(5) Expected surgical outcome: The anticipated surgical outcome aimed to pinpoint the location of seminal tract obstruction and achieve surgical recanalization.

(6) Surgical risk and disposition plan:

(a) Surgical risk:

- Intraoperative operations pose a risk of damaging the vas deferens and spermatic cord blood vessels.
- Joint laparoscopic exploration carries the potential for damage to internal organs within the

abdominal cavity.

- There is a heightened risk of postoperative complications, including incision infection, and spermatic cord and testicular adnexitis.

(b) Disposition:

- The physician is urged to execute all surgical procedures with precision, employing careful dissection and ensuring gentle movements.
- It is crucial to avoid unnecessary medical injury, particularly given the delicate nature of the vas deferens.
- Postoperative anti-infection treatment should be administered diligently to mitigate the risk of complications.

4. Discussion

The procedure of vasectomy is complicated, and improper operation can lead to damage of the vas deferens. Research data indicates the risk of infertility due to congenital hypoplasia of the vas deferens is notably higher when inguinal surgery is performed in childhood. In cases of inguinal hernia surgery, inadequate understanding of the internal anatomy of the inguinal canal, improper surgical techniques, and obscured visibility of the bleeding area can lead to ineffective separation of the hernia neck from the spermatic cord, resulting in structural and functional abnormalities in the vas deferens.

The conventional clinical approach for treating obstructive azoospermia arising from medically-induced vas deferens injury is vasectomy recanalization through open surgery. However, determining the length and precise site of obstruction in these patients is challenging. Some healthcare institutions have attempted vas deferens exploration and anastomosis through the inguinal region, but this approach is associated with high surgical difficulty and suboptimal outcomes. To address this issue, studies have proposed adjusting the surgical path to relocate the vas deferens above the pubic tubercle, facilitating tension-free anastomosis without strict length requirements.

In addressing vasectomy injuries, certain researchers have employed a combination of microsurgical techniques and laparoscopy, achieving a commendable 78% success rate in reopening the obstructed vas deferens. Building on these findings, this study took a similar approach, utilizing microscopic combined laparoscopic methods for bilateral vas deferens and epididymis exploration. The treatment plan encompassed left vas deferens epididymis anastomosis and right vas deferens recanalization. The positive outcomes from this approach were reflected in the patient's robust recovery. This study's findings lead to the conclusion that longer vas deferens defects can be effectively rectified through standardized laparoscopic surgical operation protocols. Precise separation of the severed ends was successfully accomplished, demonstrating the potential for reconstructing the reproductive tract. Notably, in patients with varying degrees of abnormality in the pelvic region, the anastomosis of the contralateral vas deferens proved to be a feasible and valuable component of achieving comprehensive reconstruction. This innovative treatment strategy offers promise for addressing diverse abnormalities in the pelvic region of the vas deferens and underscores the significance of tailored, meticulous surgical approaches for optimal patient outcomes.

The surgical management of bilateral inguinal hernia causing obstructive azoospermia encompasses three primary scenarios, each demanding a nuanced understanding of surgical intricacies by physicians.

(1) Localized vas deferens damage: In cases where the vas deferens is simply cut or ligated, and the defective section is relatively short, surgeons can excise the scar-like tissue formed at the severed end

during the operation. Subsequently, necessary anastomosis can be performed. Microscopic assistance is crucial during the operation, employing the vasectomy surgical plan for optimal outcomes.

(2) Extensive vas deferens damage: When the vas deferens damage is extensive, entering the inner pelvis and separating the inner ring region becomes challenging. For managing long vas deferens defects, a traditional open surgical plan can be employed. This involves relocating the injured area to the seminal vesicle, carefully removing it through the outer ring, and conducting anastomosis post-operation. Although this approach requires a slightly larger incision, it effectively addresses lesions on both sides simultaneously.

(3) Secondary epididymal obstruction: Surgically treating secondary epididymal obstruction poses increased difficulty. Surgeons should prioritize vasovasostomy (VV) completion, and if postoperative examination reveals no spermatozoa, vasography can confirm vas deferens patency before performing vasoepididymostomy (VE). A precise understanding of surgical nuances is imperative in these cases.

With the advancement of minimally invasive surgical techniques, laparoscopic procedures have gained prominence. Researchers have successfully utilized laparoscopy to free the distal vas deferens inside the pelvis, leading it out through the other ring area, and completing anastomosis under the microscope. This approach demonstrates promising results and contributes to the expanding scope of minimally invasive surgical applications.

Managing vas deferens injuries demands a tailored approach considering the patient's condition. Cross-anastomosis operations, while complex, can be considered. However, due to the intricacies involved, widespread adoption in medical institutions may pose challenges. Surgeons are encouraged to adapt strategies based on patient characteristics and leverage evolving minimally invasive techniques for enhanced surgical outcomes.

In this case, intraoperative exploration revealed left epididymal obstruction and right vas deferens hypoplasia, successfully alleviating the obstruction through surgical treatment. Upon discharge, the patient exhibited no evident pain in the surgical incision or bilateral testes, and there were no signs of pus or redness in the urethral orifice. The absence of abdominal distension, fever, cough, sputum, and other symptoms indicated a favorable recovery. Vital signs remained stable, and the patient's mental state was positive. Importantly, sperm presence was observed in the semen.

Inguinal hernia surgery, a primary cause of obstructive azoospermia, can be effectively addressed through surgery. The utilization of microscopic combined laparoscopic bilateral vas deferens and epididymis exploration, left vas deferens and epididymis anastomosis, and right vas deferens recanalization represents a minimally invasive surgical technique. This approach offers the advantages of minimal invasiveness and a clear surgical field of vision, ensuring precise alignment of the mucosal tissues of the vas deferens lumen. Importantly, it mitigates the issues associated with microtissue embedding, contributing significantly to the success rate of vas deferens recanalization [4-6].

To ensure the efficacy of surgical treatment, comprehensive patient assessment before surgery is essential. During surgery, a gentle approach is imperative, aiming to prevent edema and infection for the anticipated treatment effect [7,8]. Effective perioperative nursing interventions are crucial. Preoperative preparations involve thorough health education and addressing patient queries about the operation. Postoperatively, nursing staff meticulously monitor vital sign changes, ensuring smooth respiration and drainage. Patients are guided on reasonable diet and exercise, following the doctor's instructions for medication. Nursing staff provide post-discharge review information and precautions to secure the desired prognosis [9,10].

5. Conclusion

Postoperative bilateral inguinal hernia leading to obstructive azoospermia is categorized as a sperm transportation disorder resulting from medical injury, posing potential adverse effects on patients' lives. Microscopic combined laparoscopic surgery, as a minimally invasive surgical technique, proves effective in precisely addressing the obstruction. However, the technical aspects of the operation and perioperative nursing interventions demand stringent adherence to protocols. Therefore, it is imperative to enhance the perioperative comprehensive assessment of the condition, develop a thorough surgical and nursing plan, and continually refine these measures in practice. This approach ensures the successful restoration of the patient's condition.

Disclosure statement

The author declares no conflict of interest.

References

[1] Zhao J, Zhai X, Li H, et al., 2017, Report of a Case of Complex Obstructive Azoospermia with Literature Review. Journal of Modern Urology, 22(6): 456–458.

[2] Guo L, Feng L, Sun X, et al., 2021, Report of 40 Cases of Obstructive Azoospermia Treated by Microscopic Vas Deferens Epididymal Anastomosis. Jiangxi Medicine, 56(8): 1225–1226 + 1257.

[3] Zhang H, Yang X, Liu X, et al., 2020, Report of a Case of Azoospermia with Polycystic Kidney and Obstruction of Seminal Tract Dynamics and Review of the Literature. Chinese Journal of Luminal Urology (Electronic Edition), 14(5): 370–372.

[4] Li J, Luo Y, Zhang J, et al., 2021, Case Analysis of Different Epididymal Anastomosis Sites for the Treatment of Epididymal Obstructive Azoospermia. Journal of Dali University, 6(8): 62–66.

[5] He J, 2019, Perioperative Care of Patients with Obstructive Azoospermia Treated with Minimally Invasive Microscopy. Electronic Journal of Practical Clinical Nursing, 3(20): 53 + 55.

[6] Duan L, Chen Y, Yang F, et al., 2019, Clinical Predictive Value of Seminal Plasma AMH Level in Non-Obstructive Azoospermia. China Modern Physician, 57(31): 1–4 + 9.

[7] Fu W, Zhang X, Zhong X, et al., 2020, Study on the Association Between rs139790545 Polymorphism of *WNT7A* Gene and Non-Obstructive Azoospermia in Han Chinese. Chinese Journal of Prenatal Diagnosis (Electronic Edition), 12(4): 19–22.

[8] Yang J, 2019, Evaluation of the Clinical Application Value of AMH Testing for Non-Obstructive Azoospermia. Journal of Clinical Laboratory (Electronic Edition), 8(1): 21–23.

[9] Dong Y, Song Y, Zhang Y, et al., 2013, Study on Intracytoplasmic Single Sperm Injection by Epididymal or Testicular Sperm Retrieval in Obstructive Azoospermia. Chinese Journal of Experimental Surgery, 30(4): 852–854.

[10] Hao L, Shi Z, Zhang W, et al., 2016, Analysis of the Efficacy of Intracytoplasmic Monosperm Injection by Percutaneous Testicular Puncture in Obstructive Azoospermia. Electronic Journal of Clinical Medical Literature, 3(41): 8135 + 8137.

Publisher's note

Bio-Byword Scientific Publishing remains neutral with regard to jurisdictional claims in published maps and institutional affiliations.

Urology Research, 2023, Volume 1, Issue 3
https://ojs.bbwpublisher.com/index.php/UR

Analysis of the Efficacy of Flexible Ureteroscopy and Rigid Ureteroscopy with Holmium Laser Lithotripsy in the Treatment of Upper Ureteral Stones in the Elderly

Bing Zhou*

Suqian Anyi Geriatric Hospital (Sihong County Anyi Hospital), Suqian 223900, Jiangsu Province, China

***Corresponding author:** Bing Zhou, zb5460@163.com

Copyright: © 2023 Author(s). This is an open-access article distributed under the terms of the Creative Commons Attribution License (CC BY 4.0), permitting distribution and reproduction in any medium, provided the original work is cited.

Abstract: *Objective:* To compare the clinical efficacy of rigid ureteroscopy and flexible ureteroscopy with holmium laser lithotripsy in elderly patients with upper ureteral stones. *Methods:* 12 elderly cases of upper ureteral stones were selected and divided into two groups according to the type of surgery. The control group and the observation group adopted rigid ureteroscopic holmium laser lithotripsy and flexible ureteroscopic holmium laser lithotripsy, respectively. General observation indicators, laboratory indicators, and short-term efficacy-related indicators of surgery were compared between the two groups. *Results:* The operation time, ambulation time, and hospitalization time of the observation group were shorter than those of the control group, and the intraoperative blood loss was less than that of the control group ($P < 0.05$). There was no significant difference in the total primary/secondary stone clearance rate, postoperative complications, and disease recurrence rate after six months of follow-up in the two groups ($P > 0.05$). *Conclusion:* Compared with rigid ureteroscopic holmium laser lithotripsy, flexible ureteroscopic holmium laser lithotripsy for elderly patients with upper ureteral stones is more conducive to shortening the treatment and postoperative recovery time, and simultaneously, it causes no severe complications and is worthy of promotion.

Keywords: Rigid ureteroscopy; Flexible ureteroscopy; Holmium laser lithotripsy; Elderly; Upper ureteral stones

Online publication: December 30, 2023

1. Introduction

Ureteral stones are a common type of clinical emergency. It mainly refers to the temporary blockage caused by ureteral stenosis during the discharge of kidney stones. If this situation is not resolved, the stone will remain on the site longer and cause damage. Damage to the ureter can lead to clinical symptoms such as hematuria and renal colic. In severe cases, it may also lead to aggravation of hydronephrosis and renal failure, endangering the patient's life [1]. Upper ureteral stones are difficult to pass naturally due to the high obstruction position of the stone. In addition, most of the patients are elderly patients with low surgical tolerance due to factors such as their advanced

age and low immunity. Therefore, extra caution is needed in selecting surgical options [2]. It has been confirmed by many clinical cases that endoscopy combined with holmium laser lithotripsy can effectively and safely treat ureteral obstruction in elderly patients with upper ureteral stones. There are two options for endoscopy, including rigid ureteroscopy and flexible ureteroscopy. Their clinical application value requires confirmation of more clinical trials. Based on this, this study selected 12 elderly cases of upper ureteral stone as samples to evaluate the clinical efficacy of rigid ureteroscopic or flexible ureteroscopic with holmium laser lithotripsy.

2. Materials and methods

2.1. Materials

12 elderly cases of upper ureteral stones admitted from January 2020 to December 2022 were selected. They were grouped based on the surgical plan, with 6 cases in a group. There were 3 males and 3 females in the control group; age ranged from 60 to 86 years old, with an average of 67.32 ± 9.52 years; disease duration ranged from 0.5 to 5.0 years, and the mean was 2.78 ± 1.04 years. There were 4 males and 2 females in the observation group; the age ranged from 60 to 85 years old, with an average age of 65.12 ± 9.41 years; the disease duration ranged from 0.5 to 4.5 years, with an average year of 2.31 ± 0.99. The data between the groups were standardized and compared, and there was no significant difference ($P > 0.05$).

Inclusion criteria included patients who meet the relevant diagnostic criteria in the "Chinese Guidelines for the Diagnosis and Treatment of Urological Diseases" [3]; patients whose disease has been confirmed by imaging, laboratory, and other examinations; patients who meet the relevant indications of the surgical procedures used in this article; patients who are ≥ 60 years old, have clear consciousness, and can communicate normally; patients who have no history of mental, cognitive, psychological, and other diseases; patients with no missing information in their medical records; patients who have informed consent and voluntarily sign relevant documents. Exclusion criteria were patients with contraindications to surgical treatment; patients who have severe dysfunction of important organs such as the heart and brain, or malignant tumors; patients who have severe urinary system or systemic infection; patients who have blood system or immune system diseases; patients who dropped out of the study midway.

2.2. Methods

Rigid ureteroscopic holmium laser lithotripsy was performed in the control group. Patients were instructed to adopt a lithotomy position and epidural anesthesia was performed. After confirming that the anesthesia effect reached a satisfactory standard, a rigid ureteroscope was inserted until it reached the ureteral opening on the affected side. A rigid scope was used to insert a zebra guidewire and observe the surrounding stones. Once clear, the water pressure was reduced and the guidewire was slowly withdrawn. Then, a holmium laser fiber was inserted until the stone was reached, and the laser therapy instrument was turned on to perform lithotripsy. Larger stones can be removed with lithotomy forceps, while smaller stones can be flushed out directly with normal saline. After confirming that all stones had been removed, the double J tube was left to complete the operation. Relevant antibiotics should be used rationally according to routine postoperative procedures.

Flexible ureteroscopic holmium laser lithotripsy was adopted in the observation group, with the same body position and anesthesia form as the control group. After confirming that the anesthesia was in full effect, the flexible ureteroscope was slowly inserted along the expansion sheath until it reached the renal pelvis flexibly. The angle of the soft mirror was adjusted to fully explore the situation of the stone obstruction. After confirmation, the holmium laser fiber was inserted, and the same lithotripsy operation was completed as in the control group. The postoperative treatment plan was also the same as in the control group.

2.3. Observation indicators

(1) General observation indicators of surgery: The observed operation time, intraoperative blood loss, ambulation time, and hospital stay were compared in a standardized manner between the two groups.

(2) Short-term efficacy-related indicators: Statistical analysis was performed on the primary/secondary stone clearance rate and the incidence of postoperative complications (including ureteral injury, infection, urethral bleeding, etc.), and the observation results were compared between the two groups; at the same time, the patients were followed up for 6 months to perform statistical analysis and compare the recurrence rate of the disease.

2.4. Statistical analysis

Using SPSS25.0 for Windows software as the statistical basis, all the obtained data were divided by nature. Measurement data were displayed as mean ± standard deviation (SD), and a parallel *t*-test was performed; count data were displayed as %; at the same time, the chi-square test was performed. If the final *P* value was smaller than 0.05, it indicated a statistically significant difference.

3. Results

3.1. Comparison of general observation indicators of surgery between the two groups

Based on **Table 1**, after observing the general indicators of surgery in the two groups, the observed values in the observation group were all lower than those of the control group, and the difference between the groups was statistically significant, $P < 0.05$.

Table 1. Comparison of general observation indicators (mean ± SD)

Group	Number of cases	Operation time (minutes)	Intraoperative blood loss (mL)	Time to get out of bed (hours)	Length of hospital stay (days)
Control group	n = 6	52.86 ± 15.65	8.87 ± 2.68	20.11 ± 8.98	5.89 ± 1.24
Observation group	n = 6	35.29 ± 10.18	6.04 ± 1.54	9.25 ± 3.05	3.19 ± 0.78
t	-	2.305	2.243	2.805	4.515
P	-	0.044	0.049	0.019	0.001

3.2. Comparison of short-term efficacy-related indicators between the two groups

As shown in **Table 2**, there was no statistically significant difference in the primary and secondary stone clearance rates, total postoperative complications, and disease recurrence rate between the two groups, $P > 0.05$.

Table 2. Comparison of short-term efficacy-related indicators [n (%)]

Indicators		Control group (n = 6)	Observation group (n = 6)	χ^2	*P*
Primary stone clearance rate		5 (83.33)	6 (100.00)	1.091	0.296
Secondary stone clearance rate		1 (16.67)	0 (0.00)		
Postoperative complications	Ureteral injury	1 (16.67)	0 (0.00)	-	-
	Infection	1 (16.67)	1 (16. 67)	-	-
	Blood oozing from the urethral orifice	1 (16.17)	0 (0.00)	-	-
	Total value	3 (50.00)	1(16.67)	1.500	0.221
Disease recurrence rate		1 (16.17)	1 (16.17)	1.778	0.182

4. Discussion

The clinical treatment of ureteral stones must take into consideration of both the location and size of the stone. The higher the location of the stone and the larger its diameter, the less likely it is to be passed naturally, and it is challenging to rely solely on drug treatment. To achieve the ideal therapeutic effect, timely surgical treatment is necessary, but the issue lies in choosing the surgical approach [4]. Holmium laser lithotripsy is currently clinically recognized as the energy source with the best lithotripsy effect. Compared with extracorporeal shock wave lithotripsy, it not only has a higher success rate in single lithotripsy but also a shallower penetration depth. Additionally, there is no electric current in holmium laser lithotripsy, thus guaranteeing the safety of the treatment. However, it requires a longer operation time for larger stones (diameter ≥ 2 cm), which may not be ideal for elderly patients who are relatively weak and have poor tolerance for surgery. Generally, the clinical efficacy of holmium laser lithotripsy alone is insufficient to reach satisfactory standards. Therefore, some scholars suggest combining endoscopic technology with holmium laser lithotripsy to leverage the high-definition lens of ureteroscopy. It further clarifies the condition of the stone and guides doctors to perform more precise and efficient holmium laser lithotripsy operations [5-8].

A total of 12 research subjects were selected for this study and divided into two groups. The control group underwent rigid ureteroscopic holmium laser lithotripsy, and the observation group adopted flexible ureteroscopic holmium laser lithotripsy. Although there is no significant difference in the primary/secondary stone clearance rate, total postoperative complications, and recurrence rate six months after surgery between the two groups, the observation group had shorter operation time and postoperative recovery time, and less intraoperative blood loss compared with the control group, suggesting that flexible ureteroscopic holmium laser lithotripsy performed in the observation group has more application advantages. This is because the flexible ureteroscope has a smaller diameter and a twistable scope, enabling a smoother and more efficient insertion and providing the surgeon with a wider visualization. In addition, the flexibility of the turning angle also improves the accuracy of the operation to a certain extent, which is more conducive to avoiding irritation and damage to the surrounding normal tissue and effectively reducing oxidative stress. Its combination with holmium laser lithotripsy can further improve the one-time stone clearance rate and help patients obtain more satisfactory treatment outcomes [9-11].

5. Conclusion

In summary, for elderly patients with upper ureteral stones, flexible ureteroscopic holmium laser lithotripsy is recommended as the first choice of treatment. It can shorten treatment and recovery time, reduce intraoperative blood loss, and guarantee treatment safety. However, it should be noted that flexible ureteroscopy is not suitable for patients with upper urinary tract infections, infectious stones, etc. If used inappropriately, it may cause serious consequences such as bacteremia and sepsis, hence this treatment option should be fully considered based on the actual situation of the patient [12].

Disclosure statement

The author declares no conflict of interest.

References

[1] Fu C, Dong J, Zhang J, et al., 2023, Comparative Study on the Efficacy and Safety of Flexible Ureteroscopy and Rigid Ureteroscopy Holmium Laser Lithotripsy in Treating Upper Ureteral Stones. Chongqing Medicine, 52(11): 1707–1710.

[2] Tang J, Wu M, 2023, Observation on Treating Upper Ureteral Stones in Older People with Holmium Laser Lithotripsy Under Flexible and Rigid Ureteroscopy. Guizhou Medicine, 47(2): 211–212.

[3] Na Y, Ye Z, Sun Y, et al., 2014, Guidelines for Diagnosis and Treatment of Urological Diseases in China, People's Medical Publishing House, Beijing, 1.

[4] Zhou H, Wu S, Xie M, et al., 2023, Analysis of the Efficacy of Soft and Rigid Ureteroscopy and Minimally Invasive Percutaneous Nephroscopy in Treating Complex Upper Ureteral Stones. Laboratory Medicine and Clinic, 20(8): 1050–1052, 1056.

[5] Wang X, Zeng X, Wu Q, et al., 2021, Comparison of Holmium Laser Lithotripsy Under Flexible Ureteroscopy and Rigid Ureteroscopy in Treating Upper Ureteral Stones in Older People. Chinese Journal of Gerontology, 41(1): 76–78.

[6] Fan X, 2019, Comparison of the Efficacy of Minimally Invasive Percutaneous Nephroscopy and Flexible and Rigid Ureteroscopy in Treating Complex Upper Ureteral Stones. Hebei Medicine, 25(12): 2022–2025.

[7] Du D, Yang C, Lin J, 2019, Clinical Comparison of Flexible Ureteroscope and Rigid Ureteroscope Holmium Laser Lithotripsy in Treating Patients with Upper Ureteral Stones. Chinese Modern Drug Application, 13(14): 37–38.

[8] Yang Z, Wang M, 2022, Observation on the Effect of Holmium Laser Lithotripsy Under Flexible Ureteroscopy and Rigid Ureteroscopy in Treating Upper Ureteral Stones in Older People. Guizhou Medicine, 46(11): 1761–1762.

[9] Ye C, Zhu C, Song Y, 2018, Effects of Flexible Ureteroscopy and Rigid Ureteroscopy Holmium Laser Treatment on Upper Ureteral Stones on the Body's Stress Response. Chinese Medical Innovation, 15(2): 98–101.

[10] Hao X, Xia Q, Dun W, 2023, Comparison of the Efficacy of Flexible Ureteroscope Holmium Laser Lithotripsy and Rigid Ureteroscope Lithotripsy Combined with a Stone Basket in Treating Upper Ureteral Stones. Journal of Practical Clinical Medicine, 27(2): 105–108.

[11] Wang Y, Zhang Z, Li H, et al., 2021, Comparative Study of Rigid and Flexible Ureteroscopy Treating Upper Ureteral Stones. Journal of Clinical Urology, 36(3): 212–215.

[12] Han X, Liu J, Qiu J, et al., 2022, Comparison of Rigid Ureteroscopy and Flexible Ureteroscopy Holmium Laser Lithotripsy in Treating Stones in Different Parts of the Upper Ureter. Journal of Clinical Urology, 37(4): 268–272.

Publisher's note

Bio-Byword Scientific Publishing remains neutral with regard to jurisdictional claims in published maps and institutional affiliations.

Urology Research, 2023, Volume 1, Issue 3
https://ojs.bbwpublisher.com/index.php/UR

Analysis of the Effectiveness and Detection Rate of Urine Occult Blood Test in the Diagnosis of Urinary System Diseases

Xiumei Zhu[1]*, Ying Dong[2], Lei Zhang[1]

[1]Jilin University Hospital, Changchun 130000, Jilin Province, China
[2]Northeast Normal University Hospital, Changchun 130024, Jilin Province, China

***Corresponding author:** Xiumei Zhu, zhuxm@jlu.edu.cn

Copyright: © 2023 Author(s). This is an open-access article distributed under the terms of the Creative Commons Attribution License (CC BY 4.0), permitting distribution and reproduction in any medium, provided the original work is cited.

Abstract: *Objective:* To analyze the application effect and detection rate of urine occult blood test in the diagnosis of urinary system diseases. *Methods:* 80 patients with definite diagnoses of urinary system diseases admitted from February 2022 to February 2023 were selected. Their urine samples were collected, urine sediment occult blood test and urinalysis were performed on each urine sample. The test results obtained from the two methods and their turnaround time were compared. *Results:* For the positive detection rates of white blood cells, red blood cells, proteins, and casts in the urine samples, there was no significant difference between the two methods ($P > 0.05$). In addition, there was no significant difference in the detection rates of various urinary system diseases between the two methods ($P > 0.05$). Urinalysis has a significantly shorter turnaround time compared to urine sediment occult blood test ($P < 0.05$). *Conclusion:* The urine occult blood test has a high detection rate in diagnosing urinary system diseases, with satisfactory application effect.

Keywords: Urinary system diseases; Urine occult blood test; Detection rate

Online publication: December 30, 2023

1. Introduction

Urinary system diseases have a high clinical incidence, including vaginitis, prostatitis, bladder stones, kidney stones, glomerulopathy, etc. The incidence rate has increased recently [1], seriously affecting patients' daily life and work. It may also lead to other diseases, increase treatment difficulty, and even endanger life. Therefore, it is necessary to establish a definite diagnosis through relevant examinations before adopting targeted treatment plans. In recent years, the continuous improvement of medical testing technology has greatly improved the detection rate of clinical diseases, especially the popularization of automated instruments, reducing the application rate of urine occult blood testing and other methods [2]. This study analyzes the application effect and detection rate of urine occult blood testing in the diagnosis of urinary system diseases.

2. General information and methods

2.1. General information

From February 2022 to February 2023, 80 patients with urinary system diseases were selected as the subjects of this study including 49 males and 31 females, aged 20 to 74 years old, with an average age of 46.39 ± 9.16 years. There were 33 cases of acute nephritic syndrome, 20 cases of kidney stones, 19 cases of glomerulopathy, and 8 cases of renal tumors.

Inclusion criteria included patients with discomfort symptoms related to the urinary system at the time of treatment; patients with relevant test indications; patients with normal audio and visual functions; and patients with complete clinical data and informed consent.

Exclusion criteria were patients with communication disorders; patients with other severe diseases; and patients in pregnancy or lactation.

2.2. Methods

Firstly, midstream urine was collected from the patients. The patients were instructed to fast and stop taking all medications before the collection. Before urine collection, the urethral opening was cleaned. A disposable urine cup was used to collect about 30 ml of midstream urine to reduce contamination.

Secondly, the urine samples were sent for testing within 2 hours after collection to prevent cell lysis and bilirubin changes that may interfere with the test results.

Lastly, urine sediment occult blood test and urinalysis were performed for each urine sample. 10 ml of urine sample was put into a test tube, followed by centrifugation and standing for 15 minutes. After discarding the supernatant, the urine sediment was resuspended by shaking and 0.3 ml was placed on a slide for microscopic examination. One drop of sulfosalicylic acid ethanol was added to the glass slide and the microscopic results were accurately recorded. Subsequently, urinalysis was performed using the urine test strip provided by the urine analyzer. The test strip was immersed in the urine sample and placed horizontally on a paper towel to remove excess urine. It was then inserted into the urine analyzer for analysis.

2.3. Observation indicators

The positive detection rates of white blood cells, red blood cells, proteins, and casts in urine sediment occult blood tests and urinalysis, as well as the detection rates of various urinary system diseases, and the turnaround time of the two test methods were compared.

2.4. Statistical methods

SPSS version 25.0 statistical software was used to analyze the data. Count data and measurement data were represented by mean ± standard deviation (SD) and [n (%)], respectively. The former was subjected to the χ^2 test, and the latter was subjected to the t test. $P < 0.05$ indicated that the comparative data was statistically significant.

3. Results

3.1. Positive detection rates of each component

As shown in **Table 1**, when comparing the positive detection rates of each component of the two testing methods, the difference is insignificant, $P > 0.05$.

Table 1. Positive detection rates of each component [n (%)]

Testing method	White blood cells	Red blood cells	Urinary protein	Urinary casts
Urine sediment occult blood test	66 (82.50)	72 (90.00)	45 (56.25)	30 (37.50)
Urinalysis	65 (81.25)	73 (91.25)	44 (55.00)	31 (38.75)
χ^2	0.042	0.074	0.025	0.027
P	0.837	0.786	0.874	0.871

3.2. Detection rates of urinary system diseases

As presented in **Table 2**, there is no significant difference in the detection rates of various urinary system diseases between the two testing methods, $P > 0.05$.

Table 2. Detection rates of urinary system diseases [n (%)]

Testing method	Acute nephritic syndrome (n = 33)	Kidney stones (n = 20)	Glomerulopathy (n = 19)	Renal tumors (n = 8)
Urine sediment occult blood test	32 (96.97)	19 (95.00)	17 (89.47)	8 (100.00)
Urinalysis	31 (93.94)	18 (90.00)	18 (94.74)	7 (87.50)
χ^2	0.349	0.360	0.362	1.068
P	0.555	0.548	0.547	0.302

3.3. Turnaround time

As shown in **Table 3**, the urine sediment occult blood test had a longer turnaround time than urinalysis, $P < 0.05$.

Table 3. Turnaround time (mean ± SD)

Testing method	Turnaround time (hours)
Urine sediment occult blood test	8.30 ± 2.13
Urinalysis	1.03 ± 0.39
t	21.234
P	0.000

4. Discussion and conclusion

Urine occult blood is one of the routine outpatient tests. Common diseases such as urinary stones or high-incidence genitourinary system inflammation can cause urinary occult blood. Moreover, urinary occult blood only occurs in pathological conditions [3], thus it should be detected promptly with the underlying cause discovered, so that targeted treatment can be provided. Urinary system diseases exhibit symptoms such as frequent urination, urgent urination, painful urination, and hematuria [4]. They exert negative impacts on life and work, hence prompt diagnosis and treatment should be provided.

To provide accurate treatment for urinary system diseases, it is essential to establish a definite diagnosis through relevant examinations before symptomatic treatment is initiated. The urine occult blood test assesses the number of red blood cells in the urine sample and then compares it with the number of normal red blood cells in the urine. Significant number of red blood cells beyond the normal range indicates positive occult blood in urine [5,6]. This method can determine the presence of urinary system diseases. This study selected 80 patients with urinary system diseases as the research subjects, including 33 cases of nephritic syndrome, 20

cases of kidney stones, 19 cases of glomerulopathy, and 8 cases of renal tumors. Urinary system diseases often involve the kidneys, ureters, bladder, urethra, and other body parts, with main symptoms such as frequent and urgent urination, dysuria, and hematuria. Among them, nephritic syndrome, acute kidney stones, etc., are some of the more common urinary system diseases [7,8]. The results showed that the positive detection rates of each component of the two testing methods were not much different, indicating that the urine sediment occult blood test can achieve the same diagnostic performance as urinalysis, with high sensitivity and detection rates of relevant urine components [9,10].

Comparing the disease detection rates of the two testing methods, the results showed that the difference was not significant, further indicating that urine sediment occult blood test has a high efficiency in detecting urinary system diseases. The above analysis shows that the urine sediment occult blood test can detect the components in the urine and diagnose urinary system diseases. Additionally, the test method is also useful for disease prognosis [11,12], which helps to determine and adjust the treatment plan to achieve better treatment results. This study also compared the turnaround time of the two testing methods and found that the urine sediment occult blood test had a longer turnaround time than urinalysis. The more efficient urinalysis is recommended for emergency cases to avoid delaying the diagnosis and treatment [13,14].

All in all, urine occult blood testing has high application value in diagnosing urinary system diseases and is worthy of promotion.

Disclosure statement

The authors declare no conflict of interest.

References

[1] Chen J, Ji F, Zhang M, 2023, Comparison of the Effects of Urine Analyzer and Red Blood Cell Microscopy in Urine Occult Blood Testing. China Health Standards Management, 14(21): 66–69.

[2] Zhao J, Yang C, 2021, Application of Combined Detection of Urine Dry Chemical Analysis, Urine Sediment Analyzer, and Manual Urine Sediment Microscopy in Diagnosing Urinary System Diseases. Chinese and Foreign Medicine, 40(28): 191–194.

[3] Wang Y, 2021, Research on the Application and Results of Urine Occult Blood Tests in Diagnosing Urinary System Diseases. Chinese Health Nutrition, 31(35): 254.

[4] Li Z, 2021, The Effect of Urine Analyzer Test and Microscope Red Blood Cell Count Test in Urine Occult Blood Test. China Medical Device Information, 27(18): 56–58.

[5] Xu P, Zhang S, Zhang Y, et al., 2021, Enhanced Antibiotic Treatment Based on Positive Urine Dipstick Infection Test Before Percutaneous Nephrolithotomy Did Not Prevent Postoperative Infection in Patients with Negative Urine Culture. Journal of Endourology, 35(12): 1743–1749.

[6] Peng K, 2020, Discussion on the Application Value of Urine Occult Blood Test in Diagnosing Urinary System Diseases. Chinese Community Physician, 36(36): 114–115.

[7] Duan H, 2022, Effect of Urine Analyzer Test and Microscope Red Blood Cell Count Test on Urinary Occult Blood. Smart Health, 8(6): 31–33, 132.

[8] Lu Y, Ding M, Shen Q, et al., 2021, Analysis of the Application Value of Urine Analyzer and Microscope Method for Urine Occult Blood Test. Smart Health, 7(18): 25–27.

[9] Lu J, 2021, Application and Result Analysis of Urine Sediment Occult Blood Test in Diagnosing Urinary System Diseases. Chinese Modern Drug Application, 15(18): 243–245.

[10] Zhang Y, Zhou M, 2020, A Brief Analysis of the Application Value of Urine Sediment Occult Blood Test in Diagnosing Urinary System Diseases. Journal of Contemporary Clinical Medicine, 33(6): 580, 587.

[11] Zhu H, 2021, The Importance and Necessity of Urine Sediment Occult Blood Test in Diagnosing Urinary System Diseases. World Latest Medical Information Abstracts, 21(38): 215–216.

[12] Feng X, Tian H, Chen G, et al., 2021, Analysis of the Clinical Effectiveness of Two Urine Test Methods in Diagnosing Urinary System Diseases. Medical Frontiers, 11(6): 35–36.

[13] Larue L, Guevara MG, Whitley P, et al., 2021, The Cyclical and Evolving Nature of Methamphetamine Use: An Evaluation of Near Real-time Urine Drug Test Results. Journal of Addiction Medicine, 15(5): 396–405.

[14] Zhang D, 2020, Analysis of the Diagnostic Value of Urine Sediment Microscopy in Examining Patients with Urinary System Diseases. China Medical Device Information, 26(15): 143–144.

Publisher's note

Bio-Byword Scientific Publishing remains neutral with regard to jurisdictional claims in published maps and institutional affiliations.

Urology Research, 2023, Volume 1, Issue 3
https://ojs.bbwpublisher.com/index.php/UR

Evaluation of the Effect of Transurethral Resection of Bladder Tumors in the Treatment of Bladder Cancer and its Impact on CA19-9 and CA125 Levels

Peigeng Wang*

Qingdao Jiaozhou Central Hospital, Qingdao 266300, Shandong Province, China

***Corresponding author:** Peigeng Wang, 15020057958@163.com

Copyright: © 2023 Author(s). This is an open-access article distributed under the terms of the Creative Commons Attribution License (CC BY 4.0), permitting distribution and reproduction in any medium, provided the original work is cited.

Abstract: *Objective:* To evaluate the impact of transurethral resection of bladder tumors on surgical outcomes and serum tumor markers CA19-9 and CA125 in patients with bladder cancer. *Methods:* 80 patients with bladder cancer admitted to our hospital were selected and divided into two groups according to different treatment methods, with 40 cases in each group. The control group underwent open resection of bladder tumor, and the observation group adopted transurethral resection of bladder tumors. The two groups' surgical indicators and levels of serum tumor markers CA19-9 and CA125 before and after treatment were observed and compared. *Results:* The operation time, bladder irrigation time, and intraoperative bleeding volume of the observation group were less than those of the control group, and the difference was statistically significant ($P < 0.05$); Before surgery, there was no statistically significant difference in serum CA19-9 and CA125 levels ($P > 0.05$). After surgery, the serum CA19-9 and CA125 levels of the two groups of patients were significantly lower than those before surgery. Moreover, the serum CA19-9 and CA125 levels in the observation group were significantly lower than those in the control group after surgery ($P < 0.05$). *Conclusion:* Transurethral resection of bladder tumors in the treatment of bladder cancer can significantly improve various surgical indicators and reduce the levels of bladder cancer tumor markers CA19-9 and CA125. The surgical effect and prognosis are good and it is worthy of clinical application and promotion.

Keywords: Transurethral resection of bladder tumors; Bladder cancer; Effect; Serum tumor marker; CA19-9; CA125

Online publication: December 30, 2023

1. Introduction

Bladder cancer is a common malignant disease of the urinary system. The pathogenesis of this disease is still unknown. However, in recent years, the incidence of bladder cancer has gradually increased, with an elevated incidence rate in younger individuals [1]. Tumor resection is the primary method for the treatment of bladder cancer. However, open surgery has several disadvantages, such as large incisions, slow recovery, many

complications, and high recurrence rate. This treatment approach has limited efficacy and causes patients to suffer from great pain [2]. While transurethral resection of bladder tumors, as a minimally invasive surgery, not only improves patient safety but also removes tumors more thoroughly, with a lower recurrence rate [3]. Monitoring the levels of tumor markers CA19-9 and CA125 can reflect the effect of cancer treatment and control [4]. This study was conducted to evaluate the impact of transurethral resection of bladder tumors on the levels of tumor markers CA19-9 and CA125 in patients with bladder cancer and to explore its application value in improving the efficacy and prognosis of patients with bladder cancer.

2. Materials and methods

2.1. Clinical data

80 bladder cancer patients treated with surgical treatment in our hospital from January 2019 to December 2022 were selected. They were divided into two groups according to different treatment methods, with 40 cases in each group. The control group underwent open resection of bladder tumor. This group included 25 males and 15 females, aged 34–76 years old, with an average of 52.7 ± 3.8 years old; duration of disease was 12–182 days, with an average of 91.8 ± 28.5 days. There were 21 cases of single bladder tumor and 19 cases of multiple bladder tumors; 23 cases of TNM (Tumor, Node, Metastasis) stage II cancer, 13 cases of stage III, and 4 cases of stage IV. The observation group adopted transurethral resection of bladder tumors. There were 29 males and 11 females in this group, aged 32–77 years old, with an average of 52.5 ± 3.5 years old; a disease duration of 10–191 days, and an average of 92.3 ± 29.1 days. There were 21 cases of single bladder tumor and 19 cases of multiple bladder tumors; 22 cases of TNM stage II cancer, 14 cases of stage III, and 4 cases of stage IV. After statistical comparative analysis, there was no statistically significant difference in general information such as gender, age, disease duration, tumor stage, and tumor type between the two groups of patients ($P > 0.05$).

Inclusion criteria:

(1) The study subjects were treated for symptoms such as hematuria, urinary tract pain, urinary retention, and urinary tract obstruction. Tumor lesions were found through laboratory and imaging examinations. They were confirmed to be malignant tumors by surgical pathological examination, which is consistent with the clinical diagnosis of bladder cancer.
(2) The tumor TNM stage of the selected patients is stage II–IV.
(3) The selected subjects all received tumor resection surgery and met the surgical indications.
(4) The patients and their families were informed of the purpose and methods of the research before all studies were conducted; they voluntarily choose the surgical plan, join the trial, and sign the informed consent form, which is reviewed and approved by the hospital ethics committee.

Exclusion criteria:

(1) Patients with other malignant diseases.
(2) Patients with contraindications to the corresponding surgical procedures and anesthetic drugs and unable to meet the surgical requirements.
(3) Patients with heart, brain, liver, and kidney dysfunction.
(4) Patients with mental illness and unclear autonomous consciousness.

2.2. Treatment methods

Both groups of patients underwent hemodynamic index examinations, imaging examinations, blood tests, etc., before surgery. The tumor lesions were located through imaging examinations, the nature, shape, size, number, etc., of the tumors were evaluated, and surgical plans were formulated accordingly. Antibiotics were given to

prevent infection.

The control group was treated with open resection of bladder tumor. During the operation, they were placed in a supine position, and general anesthesia was used. After the anesthesia was in effect, an incision was made through the middle of the pubic bone, the bladder was incised, the tumor focus and surrounding tissue were fully exposed, and the tumor focus was partially removed. Part of the malignant tumor and the surrounding 2–3 cm bladder wall tissue were removed together with the adhesive peritoneal tissue. If the tumor was located at the ureteral orifice, the ureter should also be removed. An anastomosis was performed, the bladder cavity was flushed, and a fistula was made. Following these, the abdomen was closed, the incision was sutured, and a ureteral catheter was placed.

The observation group underwent transurethral resection of bladder tumors, using combined spinal and epidural anesthesia with the patient taking the lithotomy position. Under the guidance of the resectoscope, the actual condition of the tumor was explored and the surgical location was determined. A resectoscope electrode was used to remove the tumor and surrounding tissue, and cutting to the muscle layer. The resection ring has both the functions of electrocution and electrocoagulation. A resector was used to remove the tumor, the power of the resector was 260W. Electrocoagulation was used to stop the bleeding after resection of the tumor focus and surrounding tissue. The power of electrocoagulation was about 180W. After sufficient hemostasis, a three-lumen urinary catheter was placed for irrigation.

2.3. Observation indicators

2.3.1. Surgical indicators

The operation time, bladder irrigation time, intraoperative bleeding volume, and other surgical index values of each patient in the two groups were measured and recorded, and the average value was calculated. The intraoperative bleeding volume = 5 ml × the number of sterile hemostatic gauze used during the operation.

2.3.2. Tumor marker levels

Before surgery and 72 hours after surgery, ELISA (enzyme-linked immunosorbent assay) was used to measure the levels of tumor markers CA19-9 (cancer antigen 19-9) and CA125 (carbohydrate antigen 125) in patients with bladder cancer. The patients were tested early in the morning on the test day. 3 ml of fasting venous blood was collected using the cubital vein blood collection method. The blood sample was centrifuged at 1000 rpm for 10 minutes, and the serum was taken for tumor markers detection in the machine. A multifunctional microplate reader was used to measure the absorbance values of CA19-9 and CA125 in the serum at a (according to horseradish peroxidase marker luminescence intensity measurement) and convert to the corresponding concentration value. Human CA19-9 and CA125 ELISA detection kits were purchased from Shanghai Enzyme Biotechnology Co., Ltd. They were measured at a wavelength of 450 nm, and the clinical reference range was 0–40 U/ml for serum CA19-9 and 0–35 U/ml for serum CA125.

2.4. Statistical methods

The research database was established by integrating the input research data with Excel 2022 software. The SPSS25.0 software package was used to perform statistical comparative analysis on different research data. Measurement data such as operation time, bladder irrigation time, serum concentrations of CA19-9 and CA125, etc., were expressed in the form of mean ± standard deviation (SD), *t*-test was used for paired comparison of data between groups, and ANOVA was used for pairwise comparison of data within groups. When $P < 0.05$, the difference was statistically significant.

3. Results

3.1. Analysis of the impacts of two surgical methods for treating bladder cancer on surgical indicators

Based on **Table 1**, the operation time, bladder irrigation time, and intraoperative bleeding volume in the observation group were significantly less than those of the control group ($P < 0.05$).

Table 1. Comparison of various surgical index data of patients in the observation group and the control group (mean ± SD)

Group	Operation time (minutes)	Bladder irrigation time (days)	Intraoperative blood loss (ml)
Observation group (n = 40)	42.7 ± 7.4	1.6 ± 0.3	48.1 ± 7.2
Control group (n = 40)	76.4 ± 8.1	2.3 ± 0.6	102.3 ± 12.8
t value	16.252	5.524	19.531
P value	0.000	0.000	0.000

3.2. Analysis of the effects of two surgical treatments for bladder cancer on serum tumor markers CA19-9 and CA125 levels

Compared with before treatment, the relevant indicators of both groups of patients were reduced after treatment, and the serum CA19-9 and CA125 levels in the observation group were also significantly lower than those in the control group ($P < 0.05$), as shown in **Table 2**.

Table 2. Comparison of serum CA19-9 and CA125 levels of patients in the observation group and the control group before and after surgery (U/ml, mean ± SD)

Group	Serum CA19-9		Serum CA125	
	Before surgery	72 hours after surgery	Before surgery	72 hours after surgery
Observation group (n = 40)	90.1 ± 8.2	58.1 ± 6.2 *	82.4 ± 6.9	49.7 ± 5.3 **
Control group (n = 40)	88.8 ± 8.5	69.2 ± 7.6 △	81.9 ± 6.6	63.2 ± 7.1 △△
t value	0.581	5.986	0.273	8.068
P value	0.564	0.000	0.789	0.000

Note: Pairwise comparison of data within the group, in the observation group: *$P < 0.05$ and **$P < 0.05$ compared with before surgery; in the control group: △ $P < 0.05$ and △△ $P < 0.05$ compared with before surgery.

4. Discussion

Many surveys and research results show that more than 90% of bladder cancers originate from epithelial tissue [5]. In the early stage of the disease, urinary disorder, urinary retention, and painless hematuria are present. When diagnosed, it is generally in the middle and late stages. The clinical treatment and control methods are tumor resection combined with radiotherapy and chemotherapy [6-8].

In terms of surgical methods, they include open resection and minimally invasive transurethral resection of bladder tumors. Open resection involves large trauma and a long recovery time, demonstrating obvious shortcomings in safety and effectiveness. Patients often need multiple surgeries and one-time open surgeries are not thorough enough to remove tumor lesions, thus the recurrence rate is higher and the patient's postoperative recovery time is also longer [9]. The results of this study showed that the operation time, bladder irrigation time, and intraoperative blood loss in the observation group were less than those of the control group, and

the difference was statistically significant ($P < 0.05$). This reflects the advantages of transurethral resection, which is minimally invasive, less time-consuming, and has less intraoperative bleeding. This is because, under the guidance of the resectoscope, the surgical field of view becomes clearer during transurethral resection of bladder tumors. The observation range is increased, which not only helps to completely remove the tumor and surrounding tissue to prevent recurrence but also reduces the damage to normal tissue and facilitates postoperative recovery, thus the surgical effect is significantly better [10].

From a predictive perspective, CA19-9 and CA125 are new observation indicators for bladder cancer. Among them, serum CA19-9 originates from the embryonic stage of tissues such as the pancreas, gallbladder, and liver, and its content in normal tissues is low. When carcinogenesis occurs, its concentration in malignant tumor will increase significantly, but a single CA19-9 is not highly sensitive for early diagnosis of bladder cancer and is mainly used to monitor and predict the development of the disease [11]; CA125 is widely distributed among skin tissue, and has high sensitivity but insufficient specificity. The use of the above two indicators can help to judge the surgical effect and prognosis more accurately and with strong reliability [12]. The results of this study showed that after surgery, the serum CA19-9 and CA125 levels in the observation group were also significantly better than those in the control group ($P < 0.05$), which reflects the positive short-term effect of transurethral resection of bladder tumor in the treatment of bladder cancer. It has again been confirmed that transurethral resection is more thorough in removing tumors. In addition to the wider visual field, it avoids damage to normal tissue and reduces surgical inflammatory stress response, thus improving patient tolerance and promoting postoperative recovery. It is related to the enhancement of autoimmune function. However, there were no simultaneous statistics and group studies on the tumor recurrence rate in this study, and the selection of time points was relatively short. However, transurethral resection treatment reduces the levels of tumor markers CA19-9 and CA125. Immune regulation mechanisms involved need to be further explored.

5. Conclusion

In summary, transurethral resection of bladder tumors in the treatment of bladder cancer can significantly improve various surgical indicators and reduce the levels of tumor markers CA19-9 and CA125. The surgical effect and prognosis are good and it is worthy of clinical application and promotion.

Disclosure statement

The author declares no conflict of interest.

References

[1] Yang Z, 2022, Effect of Transurethral Needle Electrode En-Bloc Resection of Bladder Tumors in the Treatment of Non-Muscle Invasive Bladder Cancer. Journal of Chronic Diseases, 23(12): 1895–1897 + 1901.

[2] Gao L, Sheng J, Tang P, et al., 2022, Influencing Factors of Recurrence in Patients with Non-Muscle Invasive Bladder Cancer After Transurethral Resection of Bladder Tumors. Journal of Practical Cancer, 37(11): 1886–1888.

[3] Tong X, Xiao J, Chen M, et al., 2022, Analysis of the Efficacy of Transurethral Needle Electrode Bladder Tumor Enucleation in Treating Non-Invasive Bladder Cancer. Modern Oncology, 30(24): 4518–4521.

[4] Zhang G, 2021, Study on the Expression and Diagnostic Efficacy of CEA, CA19-9, CA125, and AFP in Hemodialysis CKD Patients with Malignant Tumors. International Journal of Laboratory Medicine, 42(16): 1971–1976.

[5] Yang H, Ying M, Xia J, 2022, Clinical Effects of Transurethral Holmium Laser Bladder Tumor Resection and

Transurethral Resection of Bladder Tumors in the Treatment of Patients with Superficial Bladder Cancer. Medical Equipment, 35(16): 47–50.

[6] Tian T, Wang G, Fang D, et al., 2022, Safety Analysis of Negative Pressure Suction Transurethral Bladder Tumor Resection in Treating Non-Muscle Invasive Bladder Cancer. Journal of Clinical Urology, 37(10): 783–786.

[7] Xie M, Sha W, Cui Q, et al., 2021, Preoperative Serum NLR, CA19-9, and IL-2 Levels Have Prognostic Evaluation Value in Patients with Invasive Bladder Cancer. Experimental and Laboratory Medicine, 39(3): 624–627 + 634.

[8] Yang J, 2022, Constructing a Risk Model for Bladder Cancer Recurrence Based on Urine CA19-9 and CEA. Medical Theory and Practice, 35(24): 4255–4258.

[9] Tao W, Xu M, Zhu J, et al., 2021, Comparison of the Efficacy of 980 nm Red Laser Transurethral Bladder Tumor En-Bloc Resection and Transurethral Resection of Bladder Tumors in Treating Non-Muscle Invasive Bladder Cancer. China Minimally Invasive Journal of Surgery, 21(12): 1086–1090.

[10] Wu H, Liu Y, Liu J, 2021, Clinical Effect of Transurethral Holmium Laser Resection of Bladder Tumors in the Treatment of Non-Muscle Invasive Bladder Cancer. Henan Journal of Surgery, 27(5): 68–70.

[11] Tang K, Cao G, Li X, et al., 2021, Comparison of Clinical Effects of Transurethral Holmium Laser Bladder Tumor Resection in Treating Non-Muscle Invasive Bladder Cancer. Jilin Medicine, 42(5): 1174–1175.

[12] Lin Y, 2021, Comparison of the Effects of Transurethral Bladder Tumor Enucleation and Bladder Tumor Resection in the Treatment of Non-Muscle Invasive Bladder Cancer. Fujian Medical Journal, 43(1): 102–105.

Publisher's note

Bio-Byword Scientific Publishing remains neutral with regard to jurisdictional claims in published maps and institutional affiliations.

Urology Research, 2023, Volume 1, Issue 3
https://ojs.bbwpublisher.com/index.php/UR

A Case Report of Metastatic Melanoma to the Bladder

Ana María Ortiz-Zableh[1]*, Juan Manuel Sandoval-Ojeda[1], Natalia Patiño-Covelli[1], Isabel Cristina Bolívar-Aguilera[2], Alfredo Ortiz-Azuero[3]

[1]Autonomous University of Bucaramanga, Bucaramanga, Santander, Colombia
[2]FOSCAL Clinic, Bucaramanga, Santander, Colombia
[3]Urological Center FOSCAL, Autonomous University of Bucaramanga, Santander, Colombia

***Corresponding author:** Ana María Ortiz-Zableh, aortiz779@unab.edu.co

Copyright: © 2023 Author(s). This is an open-access article distributed under the terms of the Creative Commons Attribution License (CC BY 4.0), permitting distribution and reproduction in any medium, provided the original work is cited.

Abstract: *Objective:* The objective of this report is to present the case of metastatic melanoma to the bladder, a rare and underdiagnosed condition due to its often asymptomatic characteristic. *Case presentation:* The case was a 62-year-old female patient, with a history of melanoma at the level of the first toe, with surgical and pharmacological management. The reason for consultation was hematuria. Cystoscopy revealed a single solid, erythematous lesion with necrosis and easy bleeding, and transurethral resection (TUR) was indicated. The pathology found metastatic ulcerated melanoma. Second-line treatment (pembrolizumab) was started and presented progression to the upper limbs and relapse at the bladder level. The patient died a year later. *Discussion:* Melanoma metastases to the genitourinary tract are common, but isolated bladder metastases are rare. Treatment is usually TUR of the lesion, cystectomy, chemotherapy, and radiation therapy. TUR is curative for lesions restricted to the epithelium, although radical cystectomy is usually the therapy of choice in patients with a localized tumor. Pembrolizumab has been shown to increase survival. The prognosis depends on the size and depth of the invasion. *Conclusion:* Metastatic cancer to the bladder is rare and underdiagnosed, it may be present in patients with melanoma, nonspecific urinary irritative symptoms, and hematuria. It tends to have a poor prognosis, and requires surgical treatment associated with systemic management.

Keywords: Melanoma; Neoplasm metastasis; Urinary bladder neoplasms; Hematuria; Urology

Online publication: December 31, 2023

1. Introduction

Melanoma is the best-known presentation of skin cancer. Metastatic melanoma to the bladder is rare, constituting less than 2% of cases [1,2]. However, in autopsies performed on patients with melanoma, bladder metastases have been found in 18–37% of cases [3,4], having the second highest incidence after gastric adenocarcinoma [5]. Metastatic melanoma to the bladder occurs in patients between 44 and 81 years old and no gender prevalence has been demonstrated [6].

Melanoma metastases to the genitourinary tract are frequent, but isolated bladder metastases are rare [7],

which suggests that the incidence is higher than believed. This is explained by the fact that most patients are asymptomatic, although hematuria is present in 15% of cases, being the most frequent form of clinical presentation [8].

The objective of this report is to present the case of metastatic melanoma to the bladder, an infrequent and underdiagnosed condition due to its asymptomatic characteristic.

2. Case presentation

The case was a 62-year-old female patient with a history of melanoma at the level of the first joint of the right foot that required disarticulation in 2011 with subsequent progression to the right thigh, which required inguinofemoral lymphatic draining and pharmacological management in August 2018 with pembrolizumab.

She consulted urology in September 2018 for macroscopic hematuria of one month of evolution. The patient denied having urinary irritative or obstructive symptoms as well as constitutional symptoms and had no significant toxicological history other than those reported for baseline disease.

A urinary tract ultrasound was performed which reported a solid lesion dependent on the right bladder wall measuring 1.5 x 1.5 x 1.2 cm. Cystoscopy showed a single rounded lesion, solid in appearance, at the level of the left lateral wall; the approximately 2 cm lesion was erythematous, with areas of necrosis, very congestive and easy to bleed. Its implantation base was small and not pedunculated.

It was decided not to perform cold forceps biopsy because there was a significant risk of hematuria. Instead, transurethral resection (TUR) of the lesion was indicated. The procedure was performed without complications. **Figure 1** shows the TUR findings.

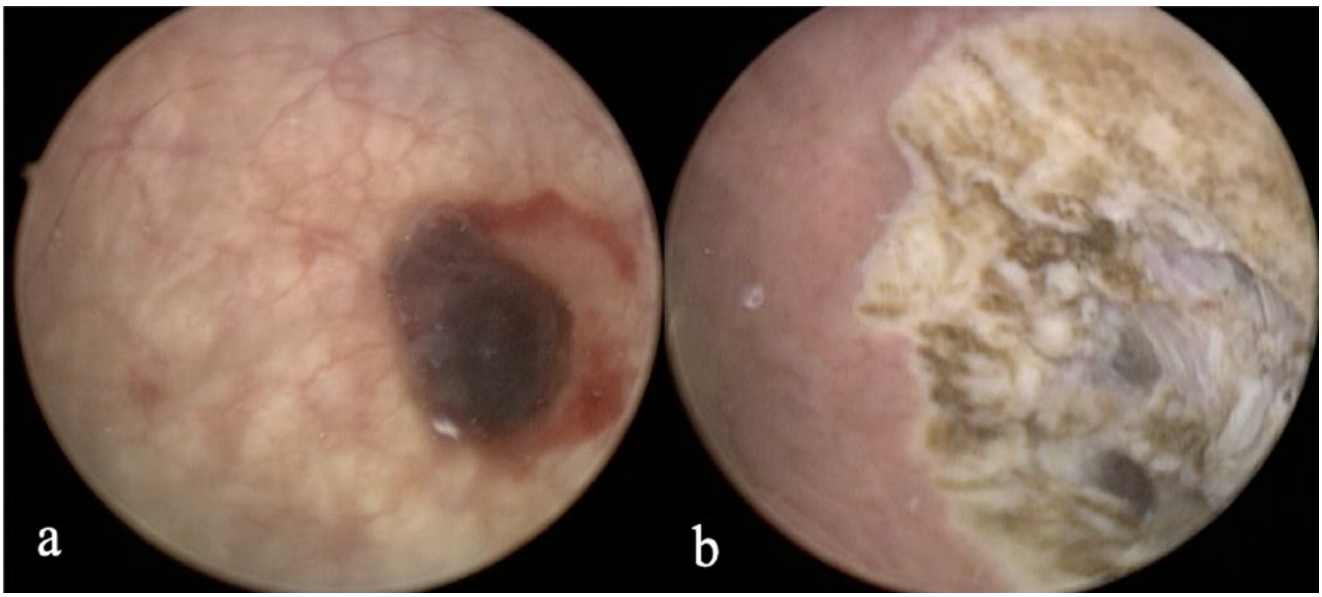

Figure 1. TUR findings a) Pre-resection with a single rounded lesion of solid appearance at the level of the left lateral wall; it was approximately 2 cm, erythematous, with areas of necrosis, very congestive, with easy bleeding, small implantation base, and not pedunculated. b) Post-resection of the lesion.

The pathology report demonstrated pathologic findings of a malignant tumor lesion, consisting of cells with atypical vesicular nuclei, prominent nucleolus, and intracytoplasmic melanic pigment. The lesion ulcerated the urothelium (**Figure 2**).

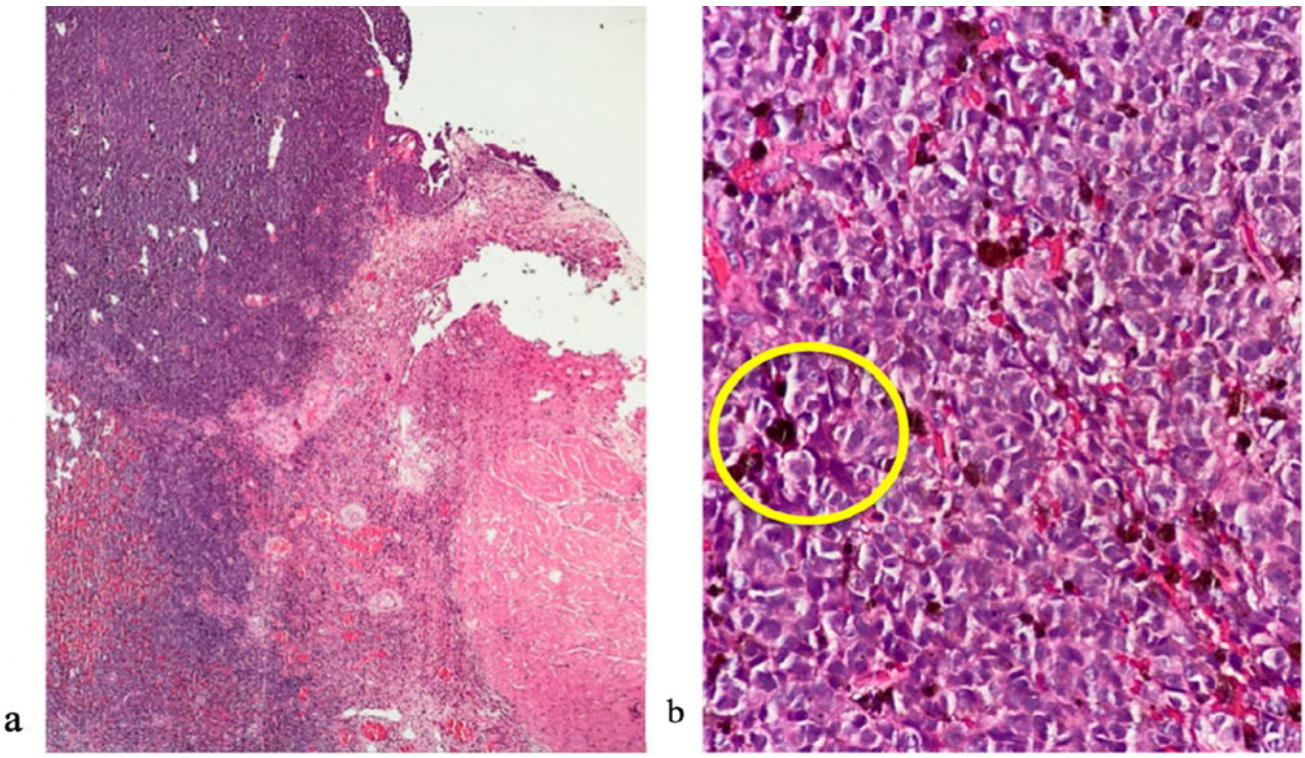

Figure 2. Histopathologic findings a) Hematoxylin & eosin 4x. There is urothelium and muscularis propria on the right side, and a malignant tumor lesion that ulcerates the epithelium on the left. b) Hematoxylin & eosin 40x. Tumor lesion is constituted by cells of atypical vesicular nuclei with prominent nucleolus and intracytoplasmic melanic pigment (yellow circle).

With these findings, it was decided that clinical oncology would manage the case, which decided to initiate second-line therapy with pembrolizumab. Despite this management, the patient presented with progression of the disease to upper limbs and recurrence at bladder level at 7 months postoperatively. She did not present new episodes of hematuria and died in August 2019 due to metastatic involvement of the disease. The patient died outside the institution, so communication was maintained with her relative who confirmed her death due to sequelae of the disease.

3. Discussion

Metastatic melanoma to the bladder is a rare and underdiagnosed condition because not all patients present associated symptoms that allow suspicion of metastatic involvement in the bladder, as in the previously reported case.

Dasgupta and Brasfield found that, in autopsies of 125 patients with melanoma, there was 18–37% of metastatic disease to the bladder [4]. Likewise, Ganem and Batal reviewed 80 cases of metastatic spread to the bladder from distant foci and found that 22.5% were secondary to melanoma, with melanoma being second in incidence only to gastric adenocarcinoma [3].

To date, less than 20 cases of primary bladder melanoma have been reported in the literature [6,8]. Regarding symptomatology, it is known that most patients are asymptomatic and only 15% present hematuria, its most frequent form of presentation [5,9]. For this reason, for patients with a previous history of melanoma who develop

voiding syndrome (dysuria, difficulty urinating, urinary urgency, pollakiuria or nocturia) and hematuria, it is recommended that endoscopic studies be performed to exclude metastatic involvement at the bladder level [8-11]. Autopsy studies have shown that up to 18% of patients with metastatic disease have unknown bladder involvement [12]. No information or studies based on Colombian or Latin American population were found within the selected articles.

At the time of cystoscopy, a single lesion with an implantation base or several lesions such as small, pigmented, and elevated nodules covering the urothelium, as found in the patient, may be evidenced [10,13]. Histopathologically, atypical melanocytic cells similar to the primary tumor are evident. The diagnosis can only be confirmed with the morphology and the positive brownish Masson-Fontana pigments [1,14].

The treatment proposed for these cases is transurethral resection of the lesion, partial cystectomy, radical cystectomy, chemotherapy, and radiotherapy. TUR is curative for lesions restricted to the epithelium [14,15], although most authors conclude that radical cystectomy is the therapy of choice for a patient with a localized tumor, since this type of tumor tends to recur after local excision [16].

PD-L1 (programmed death-ligand 1) is an immune checkpoint protein with PD-L1 and PD-L2 ligands that interact on the lymphocyte membrane and suppress T-cell activity. Two anti-PD-1 monoclonal antibody drugs (nivolumab and pembrolizumab) have been developed and are used as second-line treatments, which have demonstrated immune modulation that can translate into objective tumor responses in 30% of patients and long-term benefit in responders [17]. Pembrolizumab has been shown to improve survival in patients with metastatic melanoma who have not responded to other treatment schemes [17-19].

The choice of treatment should be based on prognosis, health status, presence or absence of local symptoms, and depth and size of the lesion. In the present case, apart from TUR, clinical oncology decided to initiate second-line treatment with pembrolizumab, since the patient presented tumor relapse while on nivolumab.

The prognosis depends on the size and depth of the invasion [14], the mean survival is usually between 6 and 7.5 months and never exceeds 3 years [8,20]. The patient presented progression of the disease to the upper limbs and recurrence at the bladder level in 7 months, with death 12 months after consulting urology.

4. Conclusion

Metastatic melanoma to the bladder is a rare and underdiagnosed disease, since very few patients present with associated symptoms. It should always be suspected in patients with a history of melanoma and non-specific urinary irritative symptoms and hematuria. For this reason, cystoscopy is recommended in all symptomatic patients with a history of melanoma. Metastatic melanoma to the bladder usually has a poor prognosis and requires surgical management with TUR (as in the reported case) or cystectomy, associated with systemic management.

Primary melanoma of the genitourinary tract is extremely rare and represents 0.2% of all melanomas. Less than 20 cases of primary melanoma of the bladder have been reported in the literature up to 2013. Its diagnosis must be confirmed with immunohistochemistry, and its treatment consists of radical cystectomy. However, it has a poor prognosis, with a high mortality rate within the first 3 years.

Disclosure statement

The authors declare no conflict of interest.

Consent for participation

The patient's authorization was obtained by means of an informed consent form.

Consent for publication

For the publication of this article, the patient authorized the manipulation of the data for academic research purposes according to resolution 8430 of 1993.

References

[1] Nualyong C, Woranisarakul V, Tantranont N, et al., 2018, Metastatic Malignant Melanoma of the Urinary Bladder: A Case Report and Review of the Literature. Siriraj Med J, 70(3): 254–259. https://he02.tci-thaijo.org/index.php/sirirajmedj/article/view/129734

[2] Bates AW, Baithun SI, 2000, Secondary Neoplasms of the Bladder are Histological Mimics of Nontransitional Cell Primary Tumours: Clinicopathological and Histological Features of 282 Cases. Histopathology, 36(1): 32–40. https://doi.org/10.1046/j.1365-2559.2000.00797.x

[3] Ganem E, Batal J, 1956, Secondary Malignant Tumors of the Urinary Bladder Metastatic from Primary Foci in Distant Organs. J Urol, 75(6): 965–972. https://doi.org/10.1016/s0022-5347(17)66911-8

[4] Dasgupta T, Brasfield R, 1964, Metastatic Melanoma: A Clinicopathological Study. Cancer, 17(10): 1323–1339.

[5] Klinger ME, 1951, Secondary Tumors of the Genito-Urinary Tract. J Urol, 65(1): 144–153. https://doi.org/10.1016/s0022-5347(17)68470-2

[6] Niederberger CS, Lome LG, 1993, Primary Malignant Melanoma of Urinary Bladder. Urology, 41(1): 72–74. https://doi.org/10.1016/0090-4295(93)90250-e

[7] Efesoy O, Cayan S, 2011, Bladder Metastasis of Malignant Melanoma: A Case Report and Review of Literature. Med Oncol, 28(1): 667–669. https://doi.org/10.1007/s12032-010-9730-x

[8] Añón-Requena MJ, Muñoz-Arias G, Ramírez-Chamorro R, 2015, Metastatic Malignant Melanoma of the Urinary Bladder. Actas Urol Esp, 39(10): 652–653. https://doi.org/10.1016/j.acuro.2015.05.009

[9] Demirkesen O, Yaycioglu O, Uygun N, et al., 2000, A Case of Metastatic Malignant Melanoma Presenting with Hematuria. Urol Int, 64(2): 118–120. https://doi.org/10.1159/000030506

[10] Casimiro-Guzmán L, Hernández-Román LU, Cruz-Contreras LH, et al., 2015, Bladder Melanoma, Case Report and Literature Review. Rev Mex de Urol, 75(5): 306–309.

[11] Moore NA, Stunell HJ, Sizer B, et al., 2015, Malignant Melanoma Metastasis to the Urinary Bladder: A Rare Cystoscopic Finding. J Clin Urol, 8(2): 143–146. https://doi.org/10.1177%2F2051415813510712

[12] Wisenbaugh ES, Stanton ML, Grimsby GM, et al., 2012, Metastatic Malignant Melanoma to the Bladder: A Case Series. Current Urology, 6(1): 53–56. https://doi.org/10.1159/000338872

[13] Meunier R, Pareek G, Amin A, 2015, Metastasis of Malignant Melanoma to Urinary Bladder: A Case Report and Review of the Literature. Case Rep Pathol, 2015(2015): 1–6. https://dx.doi.org/10.1155%2F2015%2F173870

[14] Venyo AK-G, 2014, Melanoma of the Urinary Bladder: A Review of the Literature. Surg Res Pract, 2014(2014): 1–13. https://dx.doi.org/10.1155%2F2014%2F605802

[15] Khan M, O'Kane D, Plessis JD, et al., 2016, Primary Malignant Melanoma of the Urinary Bladder and Ureter. Can J Urol, 23(1): 8171–8175. https://pubmed.ncbi.nlm.nih.gov/26892061/

[16] Lamichhane N, Dhakal HP, 2016, Melanoma of Urinary Bladder Presented as Acute Urine Retention. J Urol Res, 3(3): 1054. https://www.researchgate.net/publication/303451018_Melanoma_of_Urinary_Bladder_Presented_as_

Acute_Urine_Retention

[17] Specenier P, 2017, Pembrolizumab Use for the Treatment of Advanced Melanoma. Expert Opin Biol Ther, 17(6): 765–880. https://doi.org/10.1080/14712598.2017.1309388

[18] Deeks ED, 2016, Pembrolizumab: A Review in Advanced Melanoma. Drugs, 2016(76): 375–386. https://doi.org/10.1007/s40265-016-0543-x

[19] Lee CSD, Komenaka IK, Hurst-Wicker KS, et al., 2003, Management of Metastatic Malignant Melanoma of the Bladder. Urology, 62(2): 351. https://doi.org/10.1016/s0090-4295(03)00354-6

[20] Crosby T, Fish R, Coles B, et al., 2018, Systemic Treatments for Metastatic Cutaneous Melanoma. Cochrane Database Syst Rev, 2(2). https://dx.doi.org/10.1002%2F14651858.CD001215.pub2

Publisher's note

Bio-Byword Scientific Publishing remains neutral with regard to jurisdictional claims in published maps and institutional affiliations.

Integrated Services Platform of International Scientific Cooperation

Innoscience Research (Malaysia), which is global market oriented, was founded in 2016.Innoscience Research focuses on services based on scientific research. By cooperating with universities and scientific institutes all over the world, it performs medical researches to benefit human beings and promotes the interdisciplinary and international exchanges among researchers.

Innoscience Research covers biology, chemistry, physics and many other disciplines. It mainly focuses on the improvement of human health. It aims to promote the cooperation, exploration and exchange among researchers from different countries. By establishing platforms, Innoscience integrates the demands from different fields to realize the combination of clinical research and basic research and to accelerate and deepen the international scientific cooperation.

Cooperation Mode

Clinical Workers

In-service Doctors

Foreign Researchers

Hospital

University

Scientific institutions

BIQ-BYWORD
SCIENTIFIC PUBLISHING PTY LTD

OUR JOURNALS

The *Journal of Architectural Research and Development* is an international peer-reviewed and open access journal which is devoted to establish a bridge between theory and practice in the fields of architectural and design research, urban planning and built environment research.

Topics covered but not limited to:

- Architectural design
- Architectural technology, including new technologies and energy saving technologies
- Architectural practice
- Urban planning
- Impacts of architecture on environment

Journal of Clinical and Nursing Research (JCNR) is an international, peer reviewed and open access journal that seeks to promote the development and exchange of knowledge which is directly relevant to all clinical and nursing research and practice. Articles which explore the meaning, prevention, treatment, outcome and impact of a high standard clinical and nursing practice and discipline are encouraged to be submitted as original article, review, case report, short communication and letters.

Topics covered by not limited to:

- Development of clinical and nursing research, evaluation, evidence-based practice and scientific enquiry
- Patients and family experiences of health care
- Clinical and nursing research to enhance patient safety and reduce harm to patients
- Ethics
- Clinical and Nursing history
- Medicine





Journal of Electronic Research and Application is an international, peer-reviewed and open access journal which publishes original articles, reviews, short communications, case studies and letters in the field of electronic research and application.

Topics covered but not limited to:

- Automation
- Circuit Analysis and Application
- Electric and Electronic Measurement Systems
- Electrical Engineering
- Electronic Materials
- Electronics and Communications Engineering
- Power Systems and Power Electronics
- Signal Processing
- Telecommunications Engineering
- Wireless and Mobile Communication